

Flow Measurement Techniques from Medical Modalities for Computational Fluid Dynamics

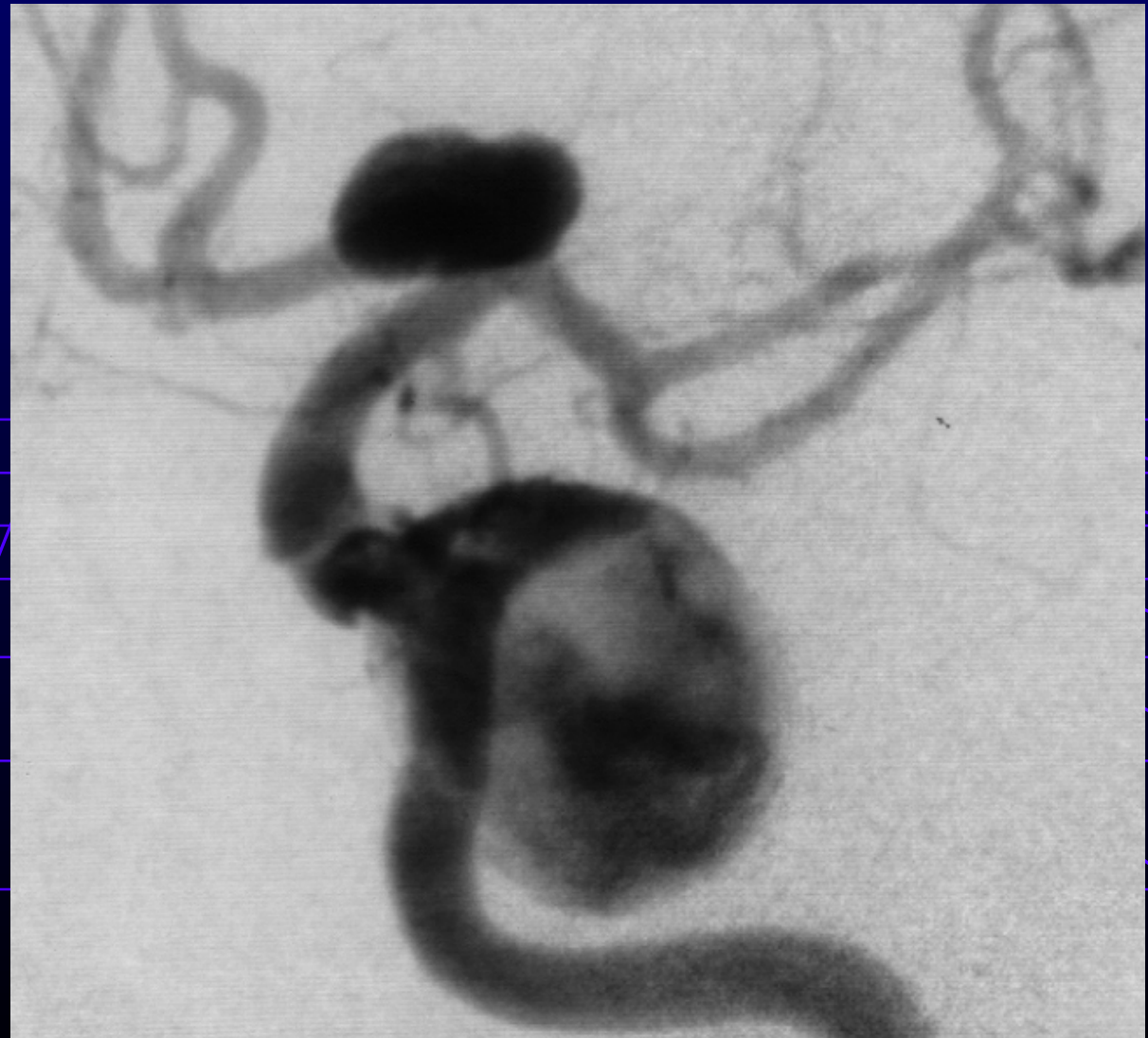
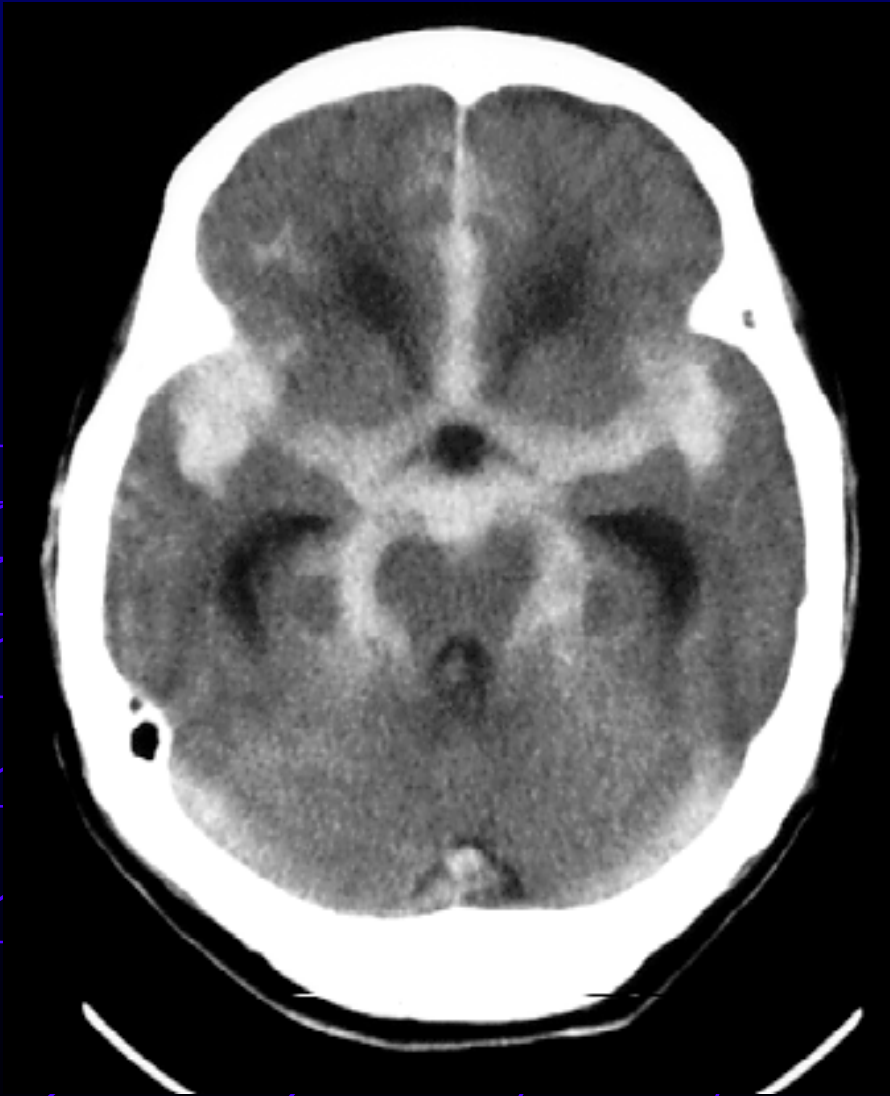
Fukasaku K^{###}, Negoro M^{*}

Riken[#],

Department of Neurosurgery Motojima General Hospital^{##}

Department of Neurosurgery Fujita Health University^{*}

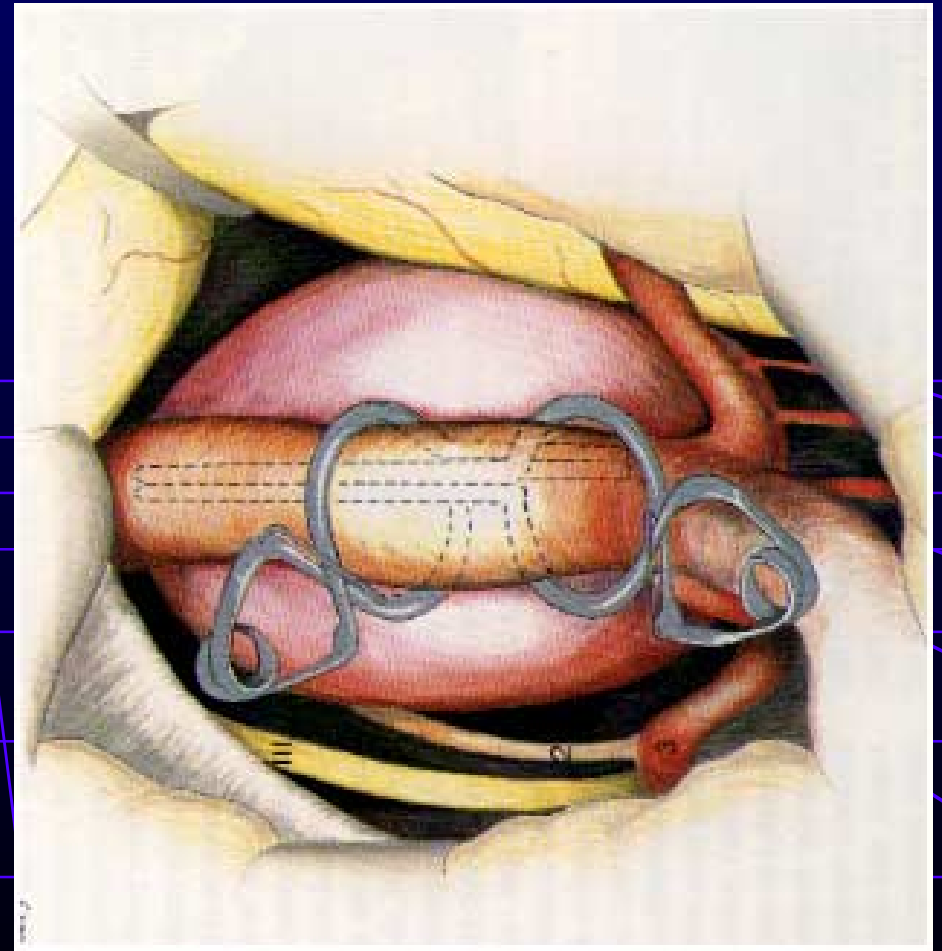
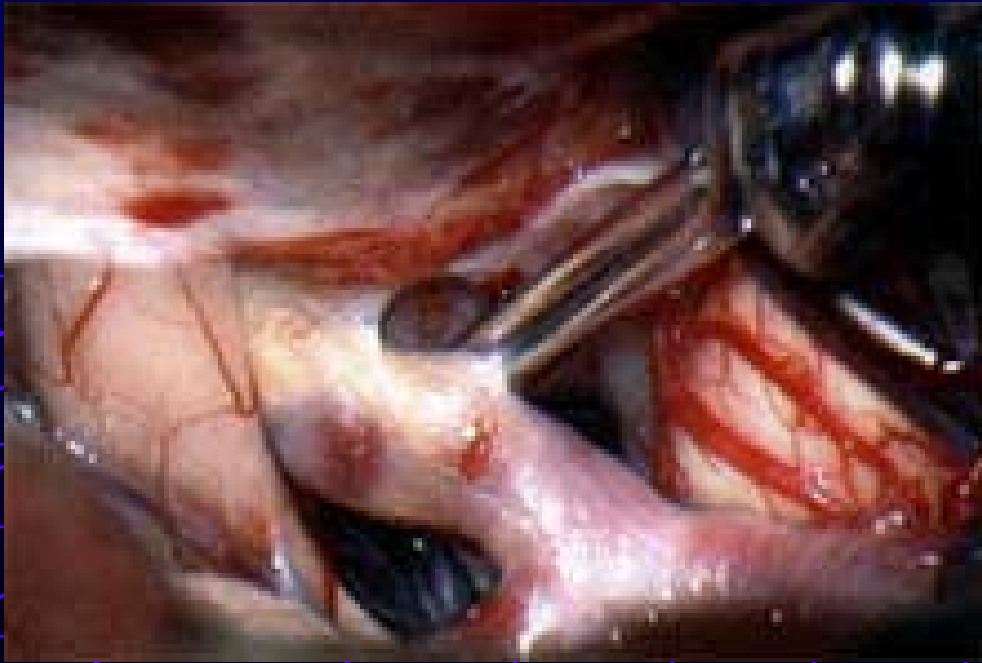SAH



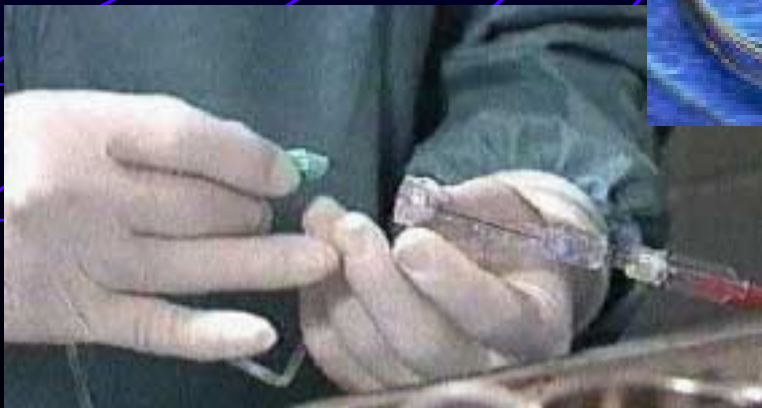
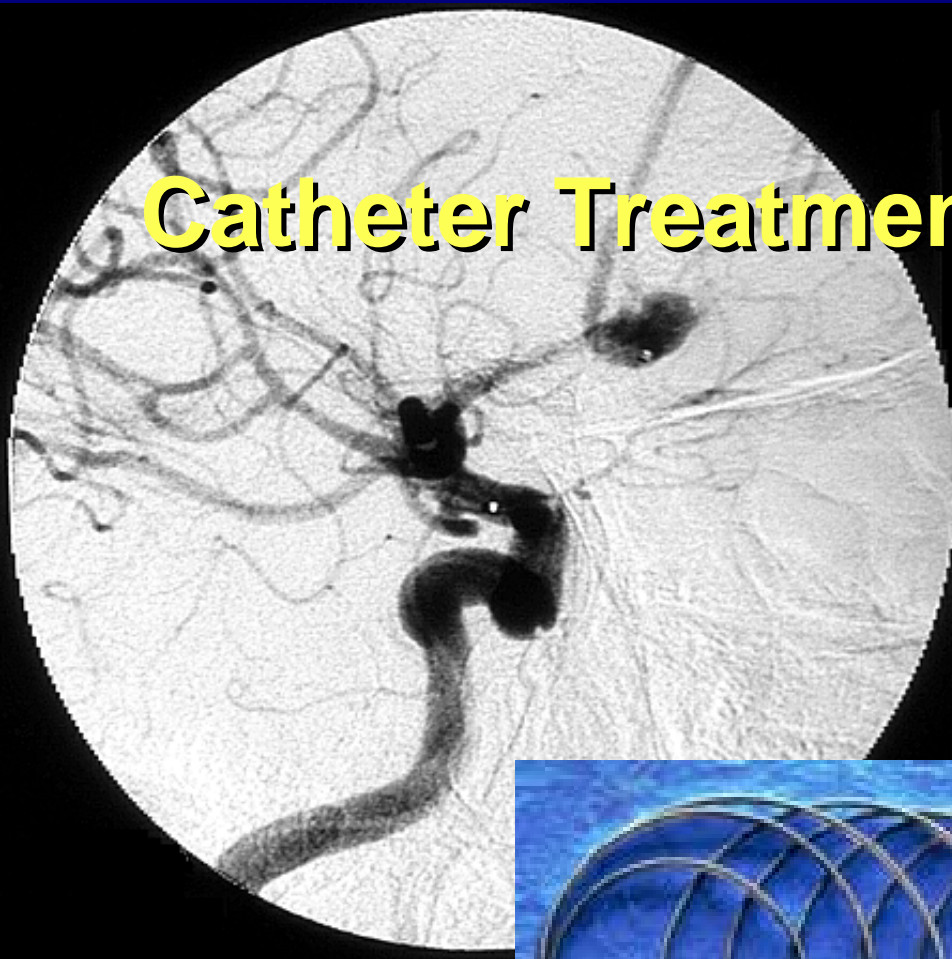
SAH Course

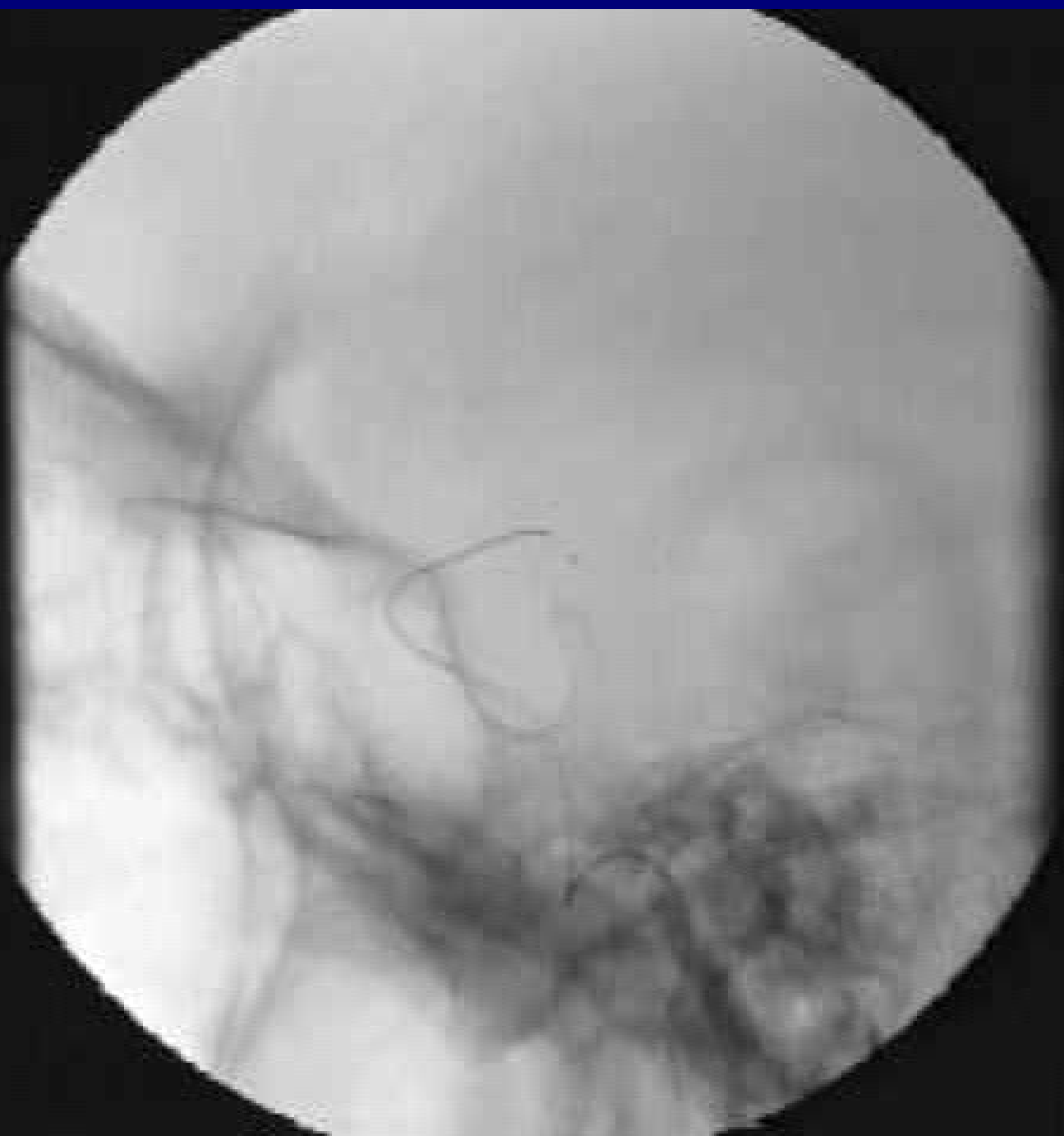	患者数など	破裂率	破裂に関する因子
Yasui 1997	234 症例 1969 - 92	2.3 % / Yr	多発
Rinkel 1998	3907 Pt-Yr	1.9 % / yr	症候性、女性、 大きなもの、 後頭蓋、多発
ISUIA 1998	727 症例、非出血 バイアス強	0.05 % /Yr (<1 cm) 1 % / Yr (>1 cm)	サイズ
ISUIA 1998	722 症例 バイアス強	0.5 % /Yr (<1 cm) 1 % / Yr (>1 cm)	なし
Juvela 2000	142 Pt, 181 An	1.3 % /Yr	喫煙 年齢 サイズ

Craniotomy

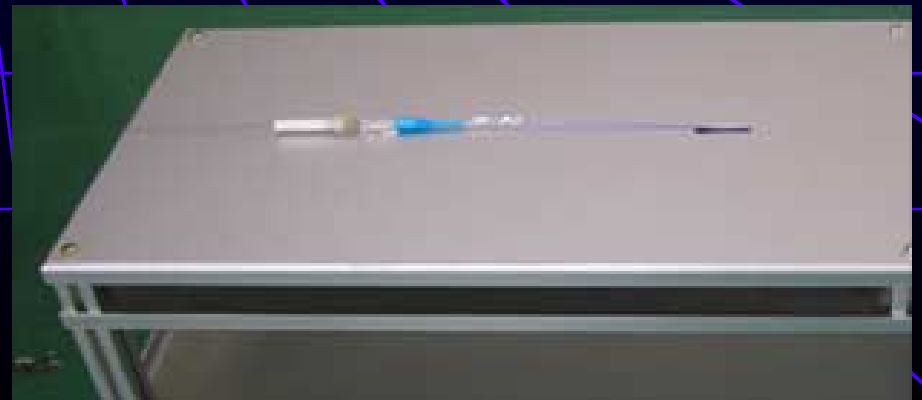
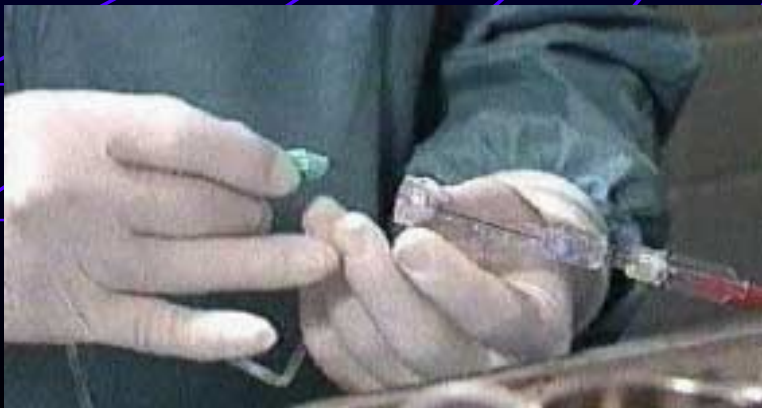
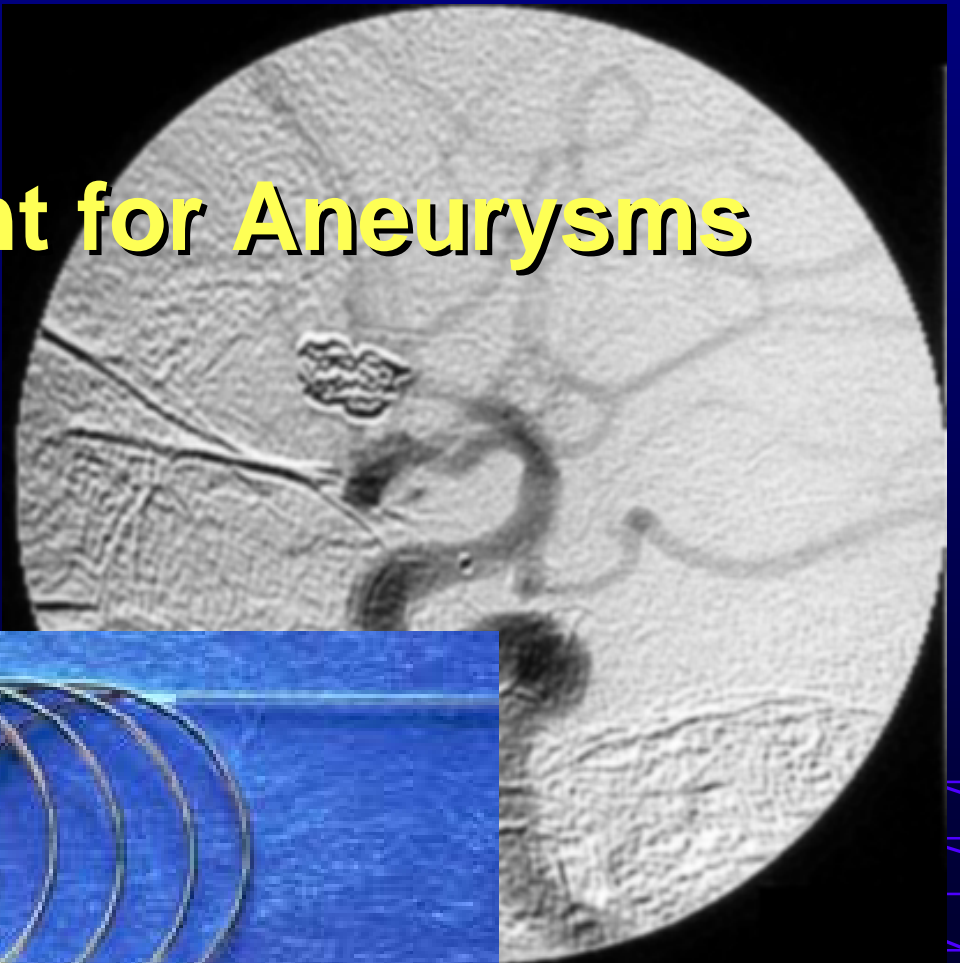
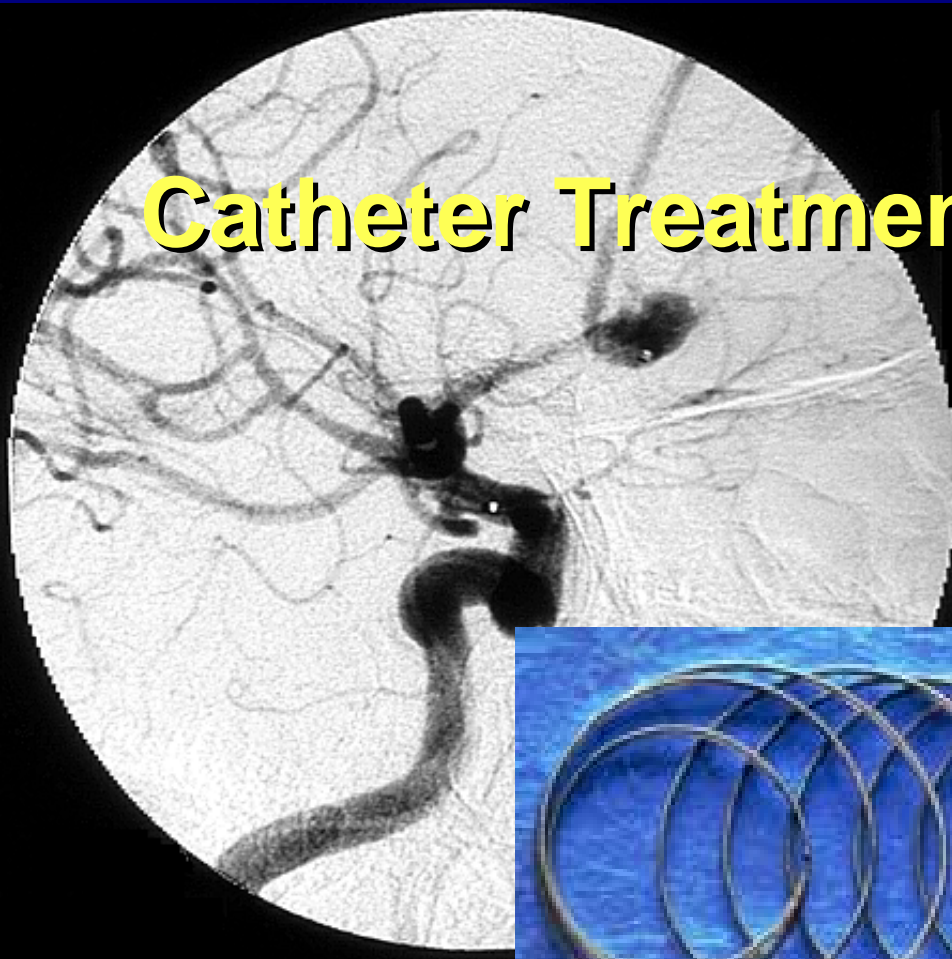


Catheter Treatment for Aneurysms

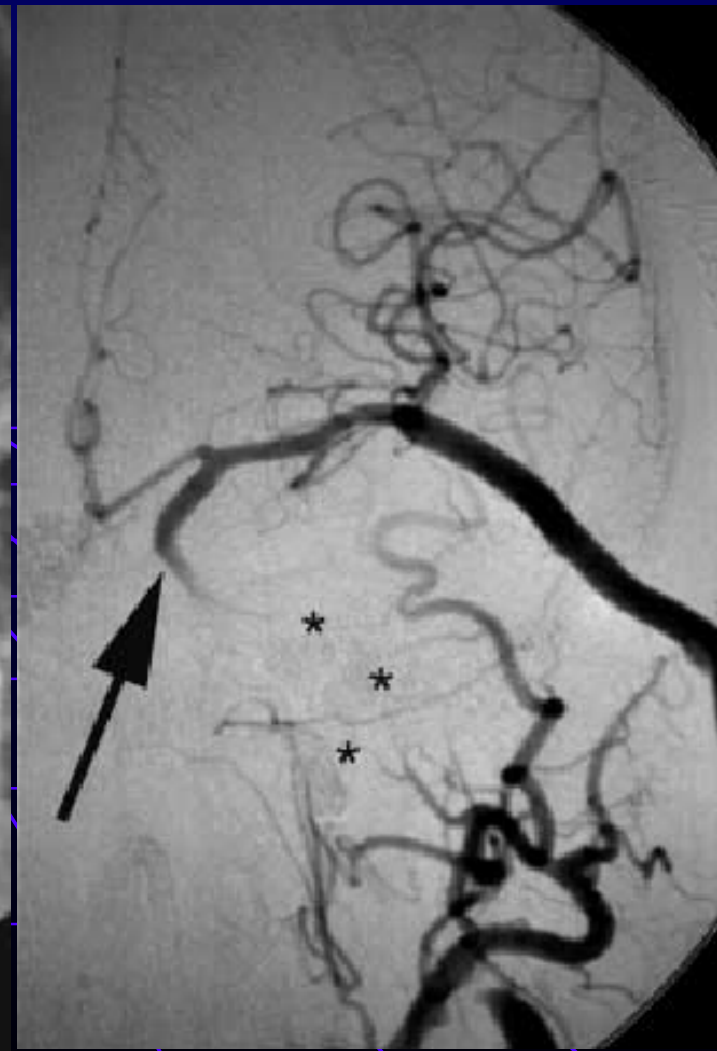
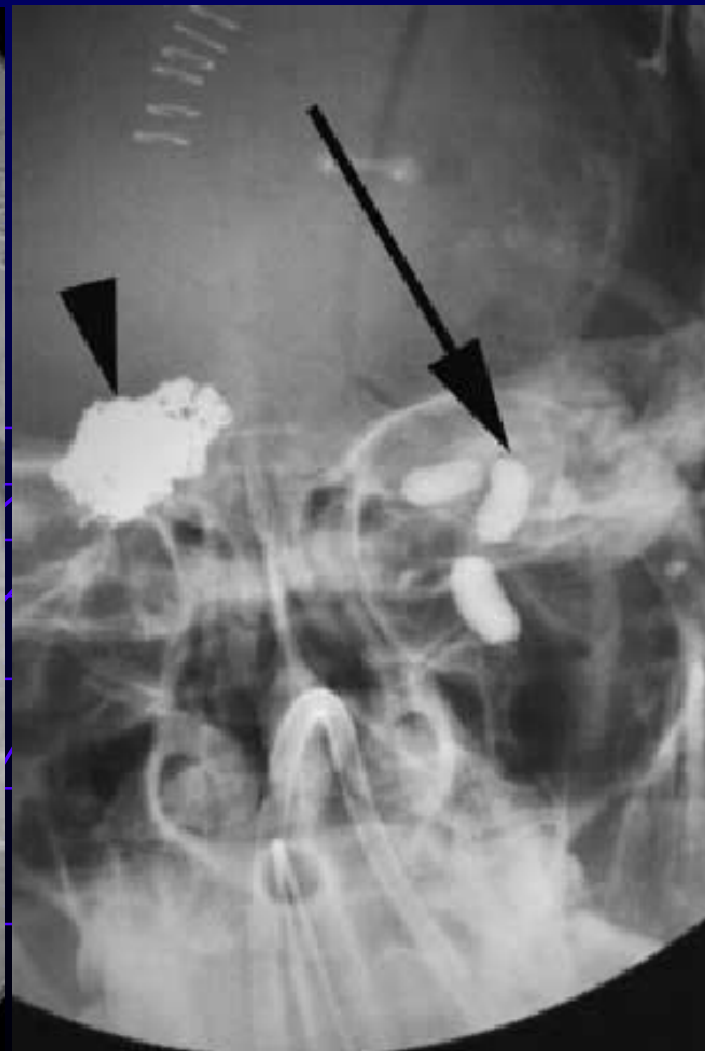
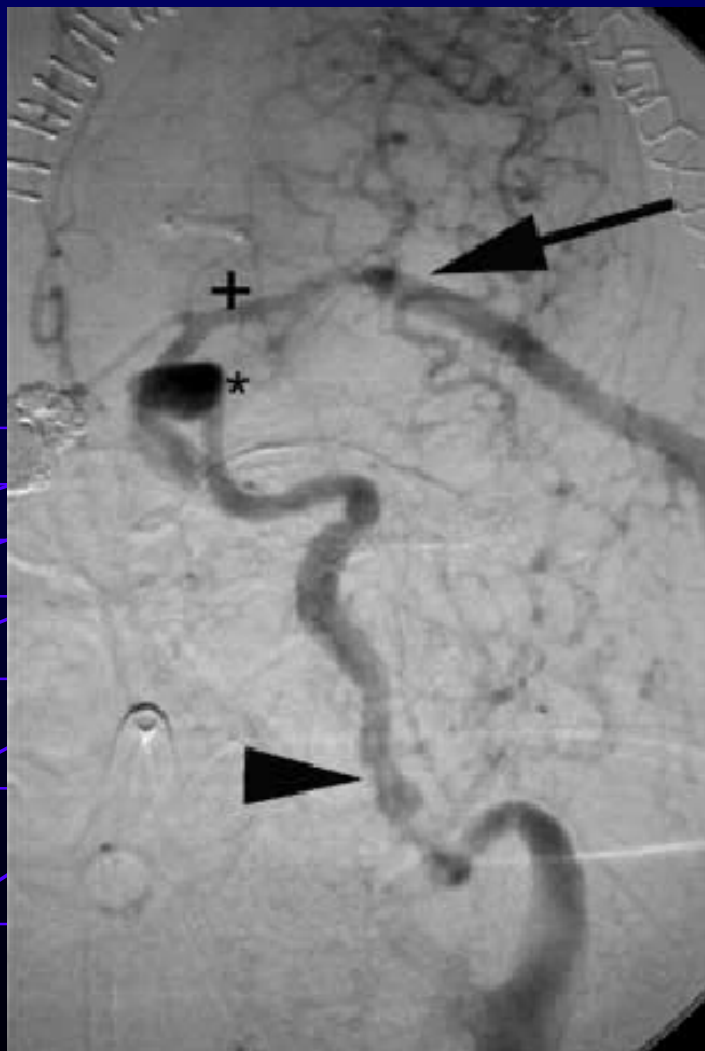




Catheter Treatment for Aneurysms

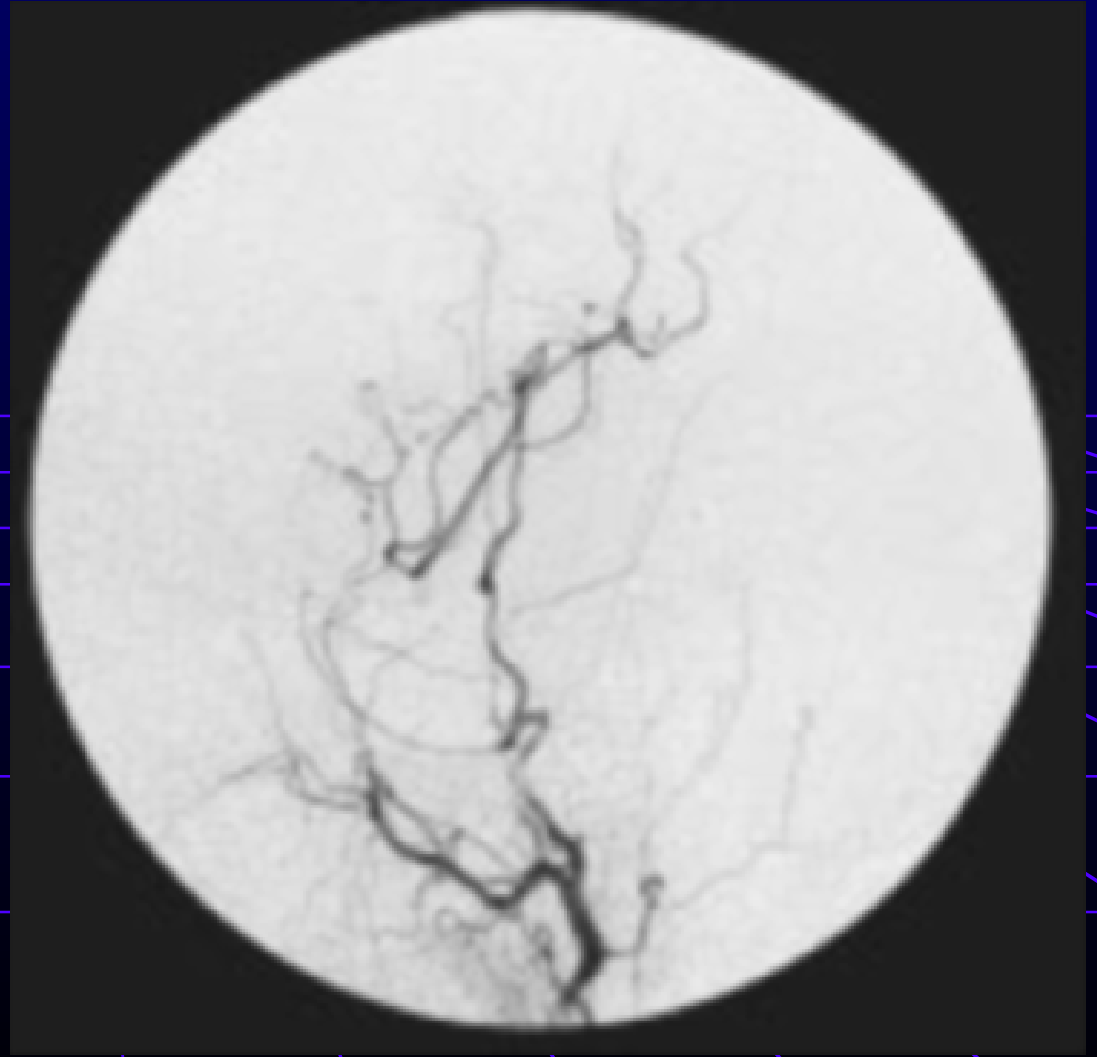
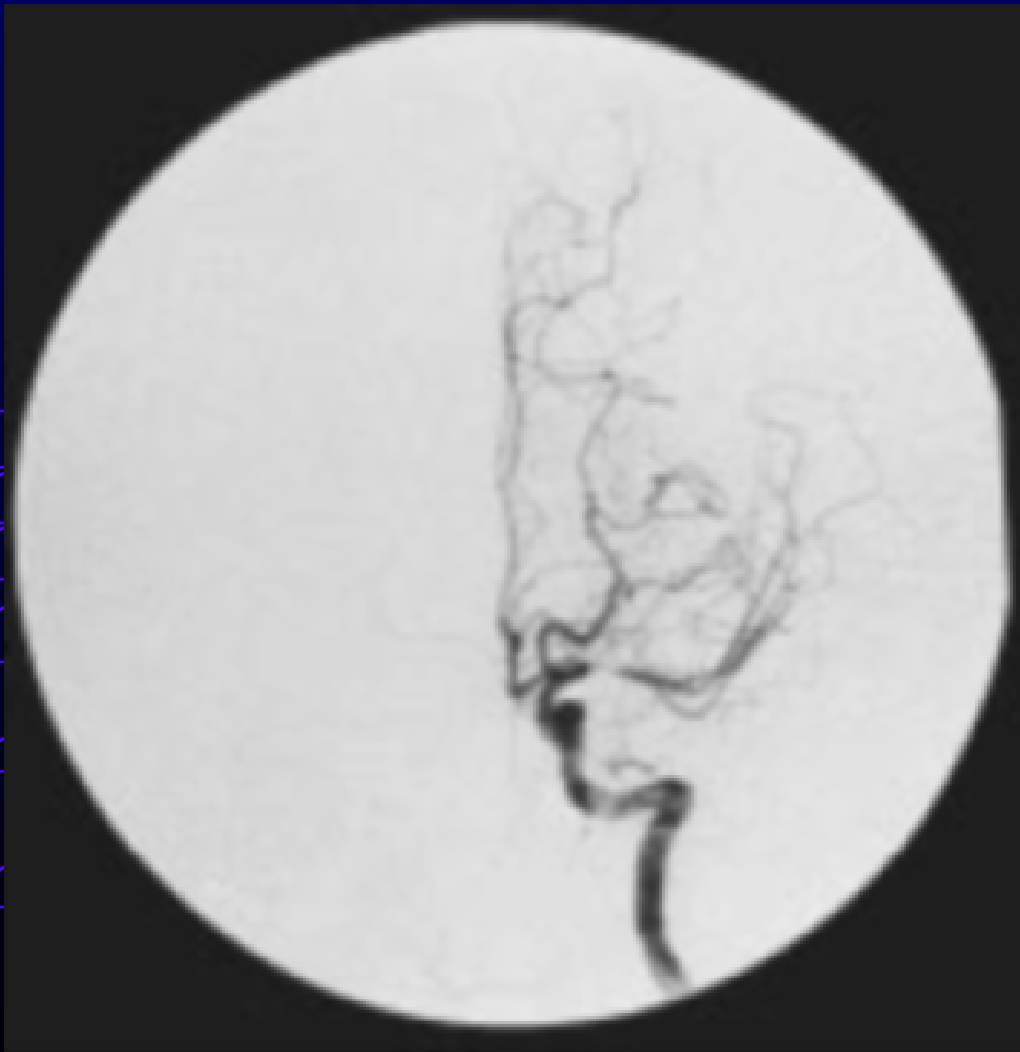

Trapping



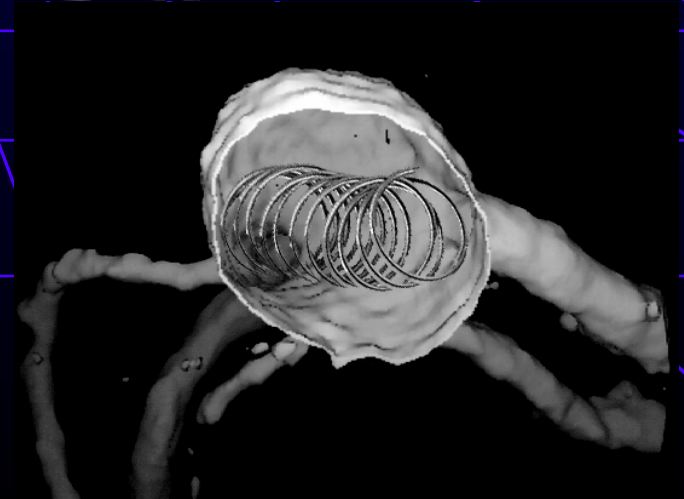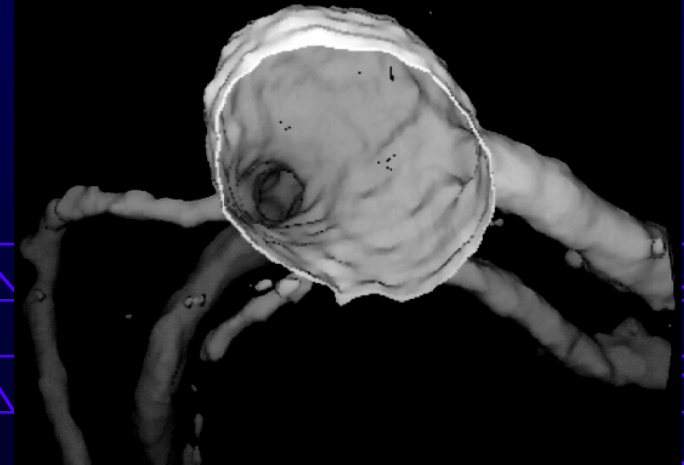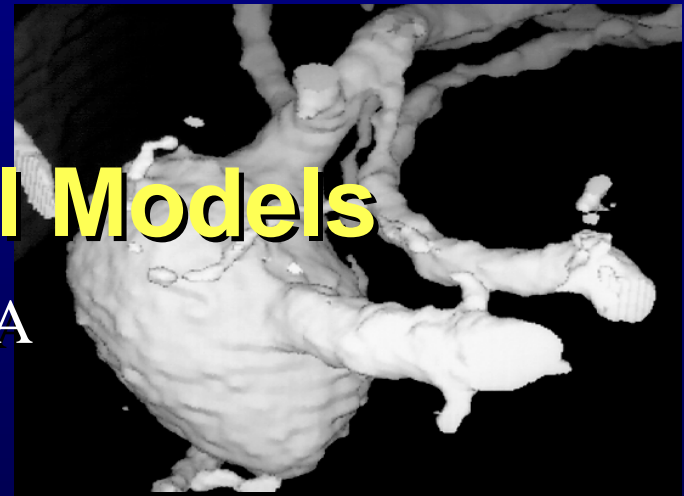
Cerebral Infarction & Treatment

- STA-MCA Anastomosis



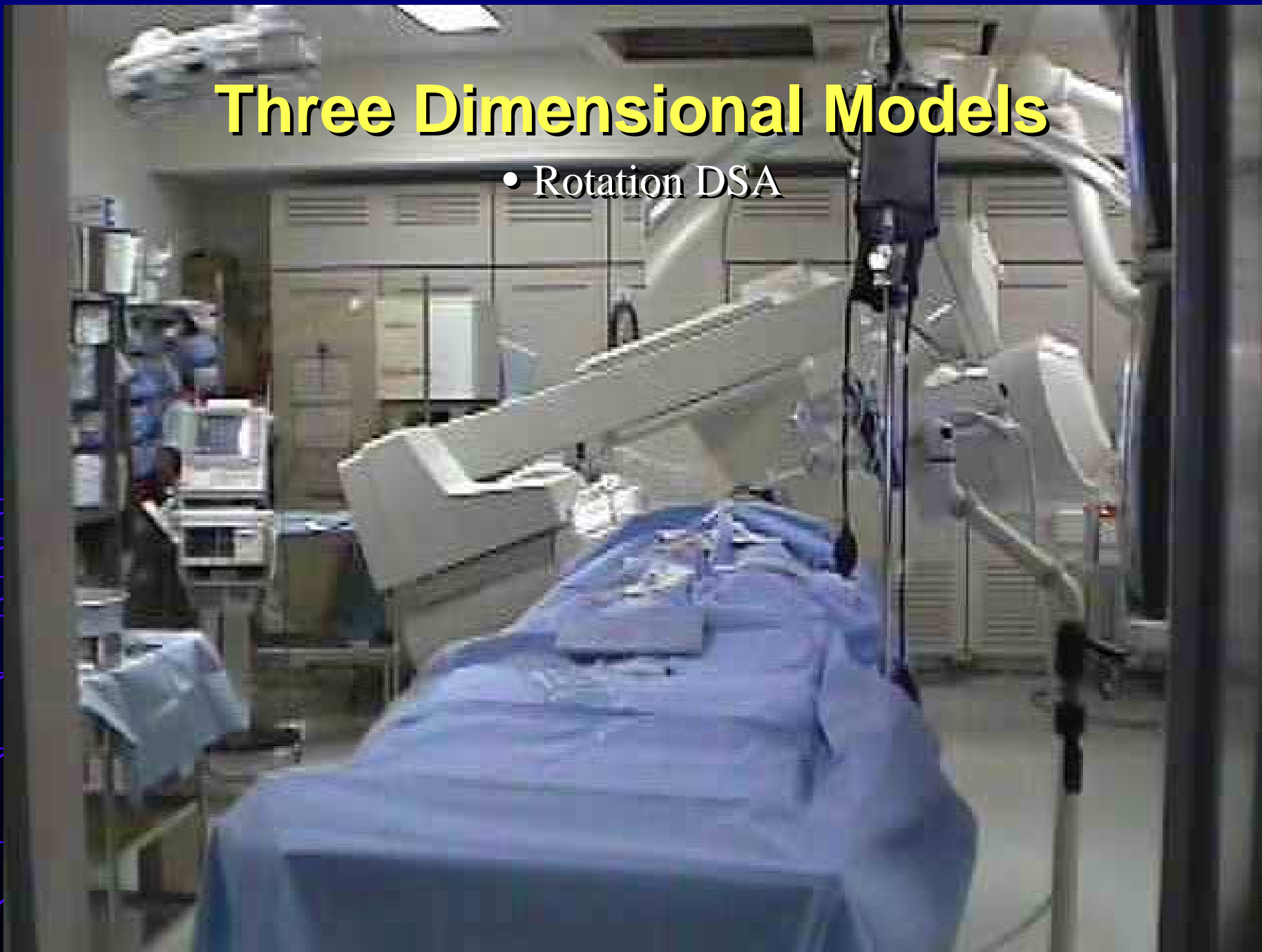Three Dimensional Models

- 3D CTA or MRA

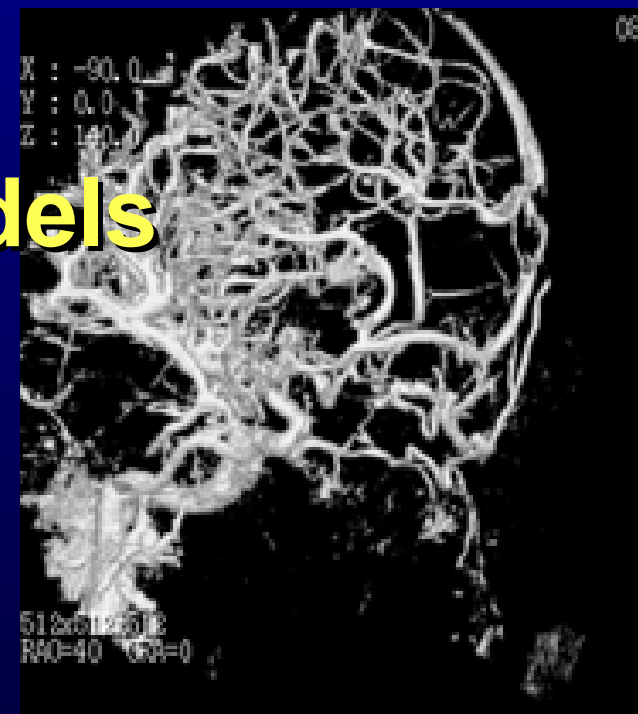
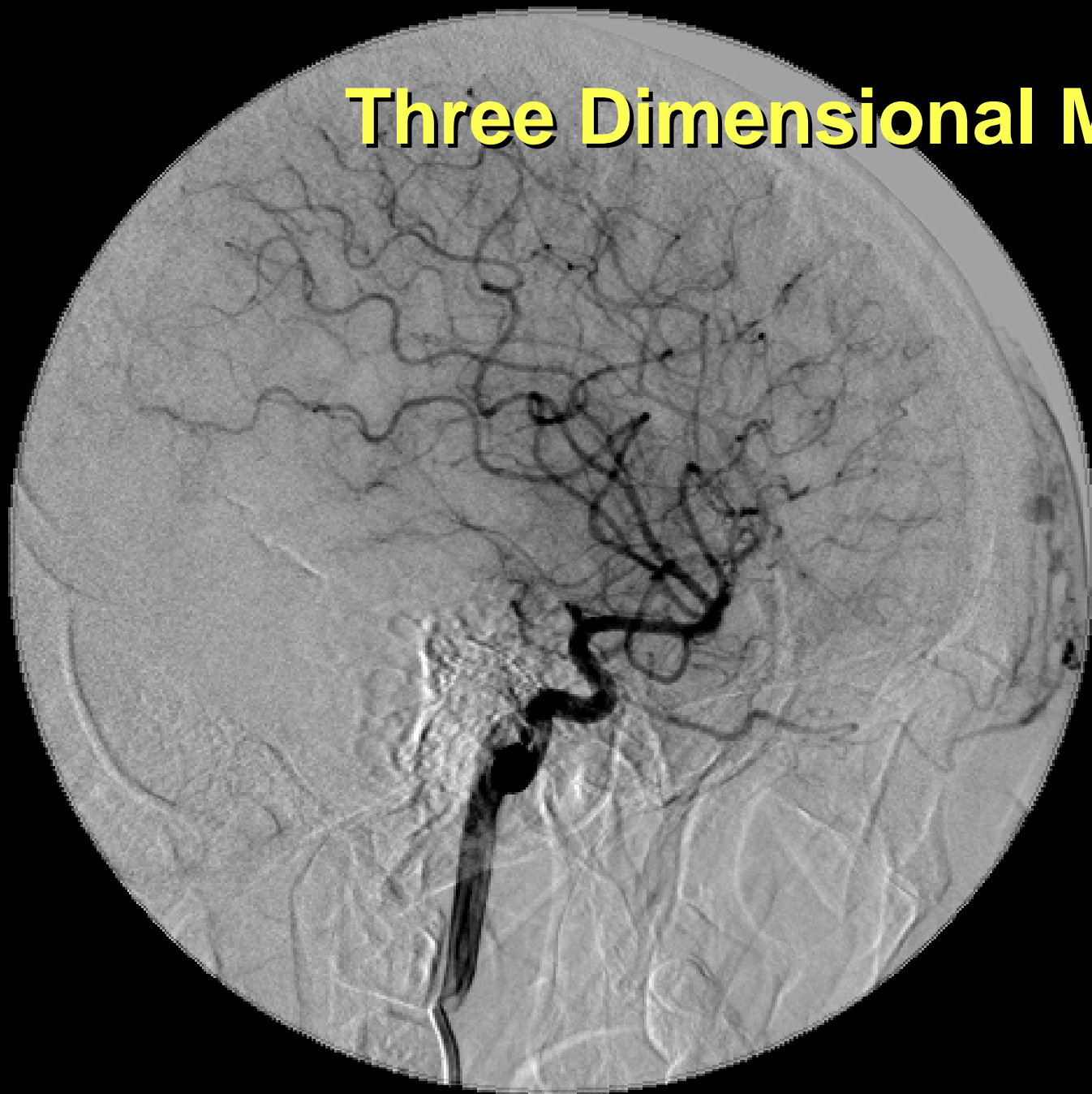


Three Dimensional Models

- Rotation DSA

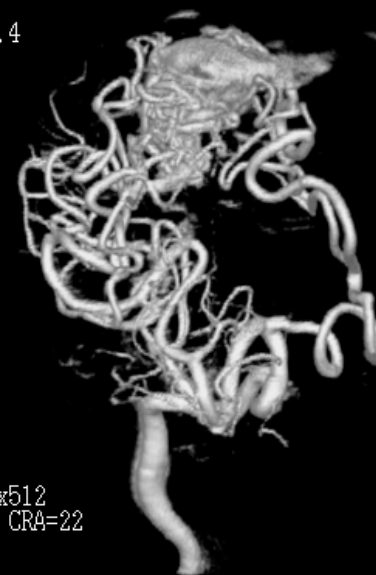

Three Dimensional Models



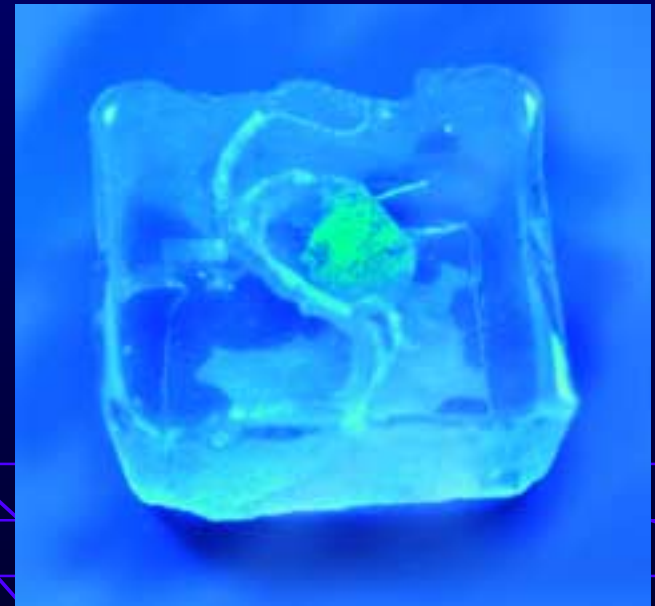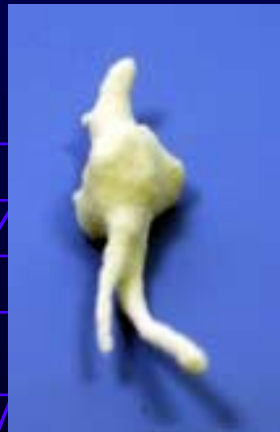


X : -70.3
Y : 3.4
Z : 149.4

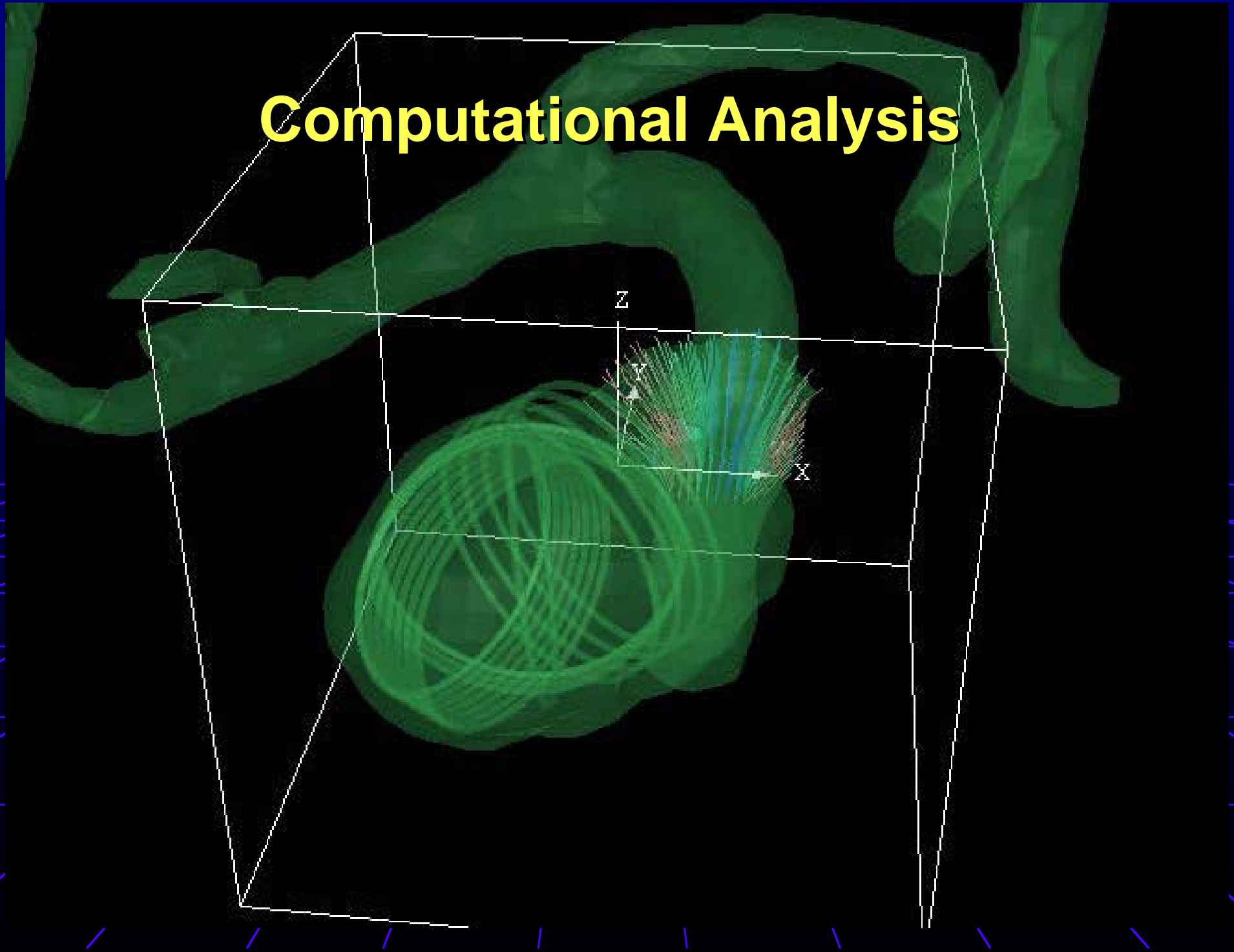
512x512x512
RAO=28 CRA=22



Three Dimensional Real Model



Computational Analysis



Introduction

- CFD without Flow Velocity Information
- **Boundary Condition**
 - Pressure
 - Velocity
 - MR
 - Ultrasound
 -
 - Compress? Non-Compress?
 - Wall Elastance?


Pressure

- Measure Using Transducer
 - Diagnostic Catheter
 - Microcatheter
- Smart Wire
 - Sensor Mounted at the Tip of Guidewire


Velocity

- MR
 - Phase Contrast
 - Phase Shift by Movement
 - Arterial Spin Labelling
 - Particle Tracking
- Doppler Sonography
 - Doppler Shift
- DSA
 - Tracking Contrast Material
 - Particle Tracking

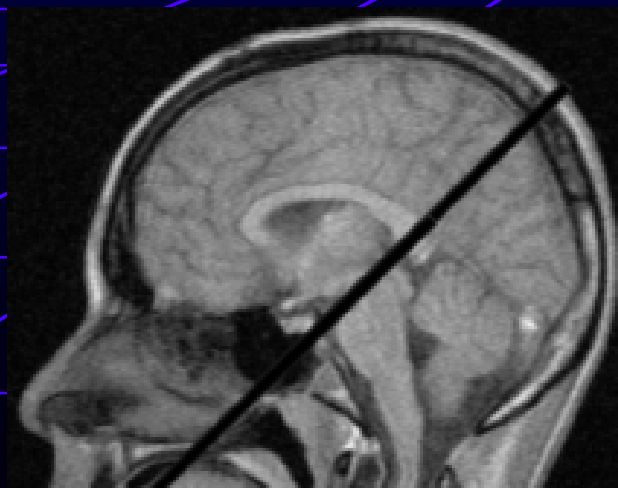
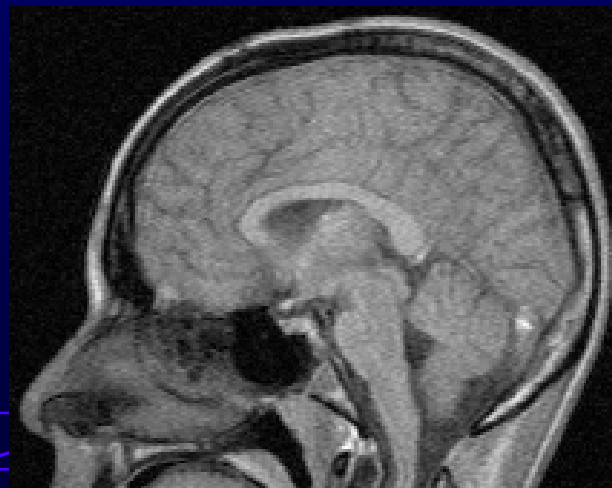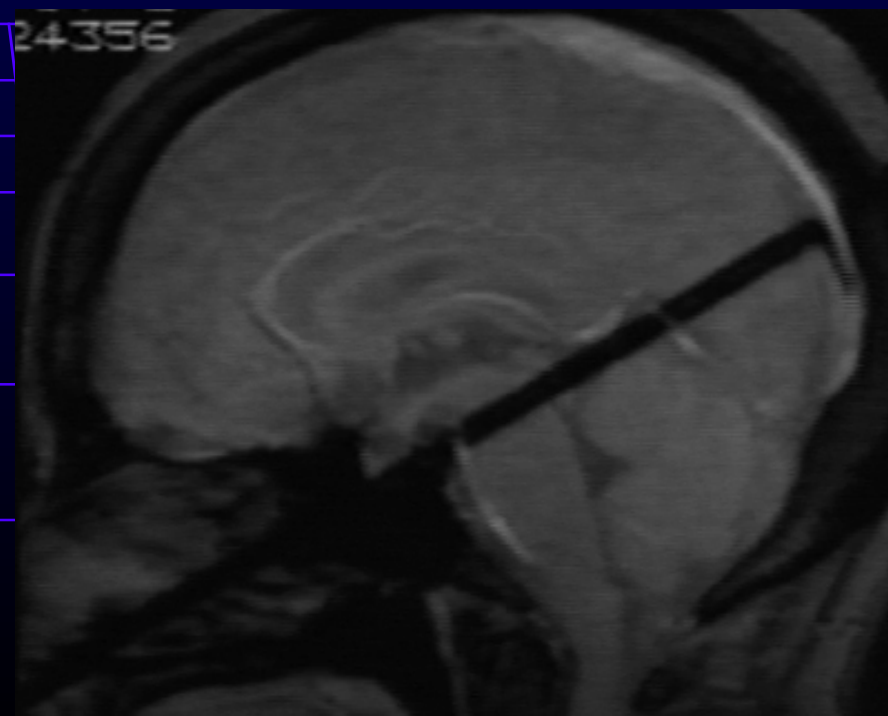
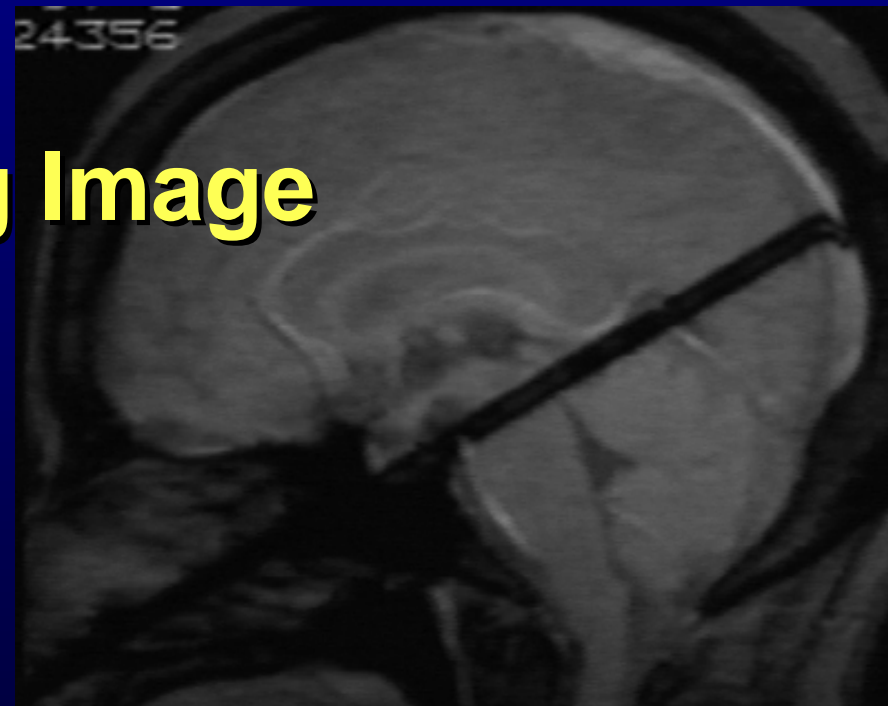
Phase Contrast MR Angiography



Phase Contrast MR Angiography



Tagging Image



Tagging Image

F/65
878749.0
01383
84024356
FE/256
TR+24
TE+12
FLY+02
PAT+726
SCD+526
NDC+2

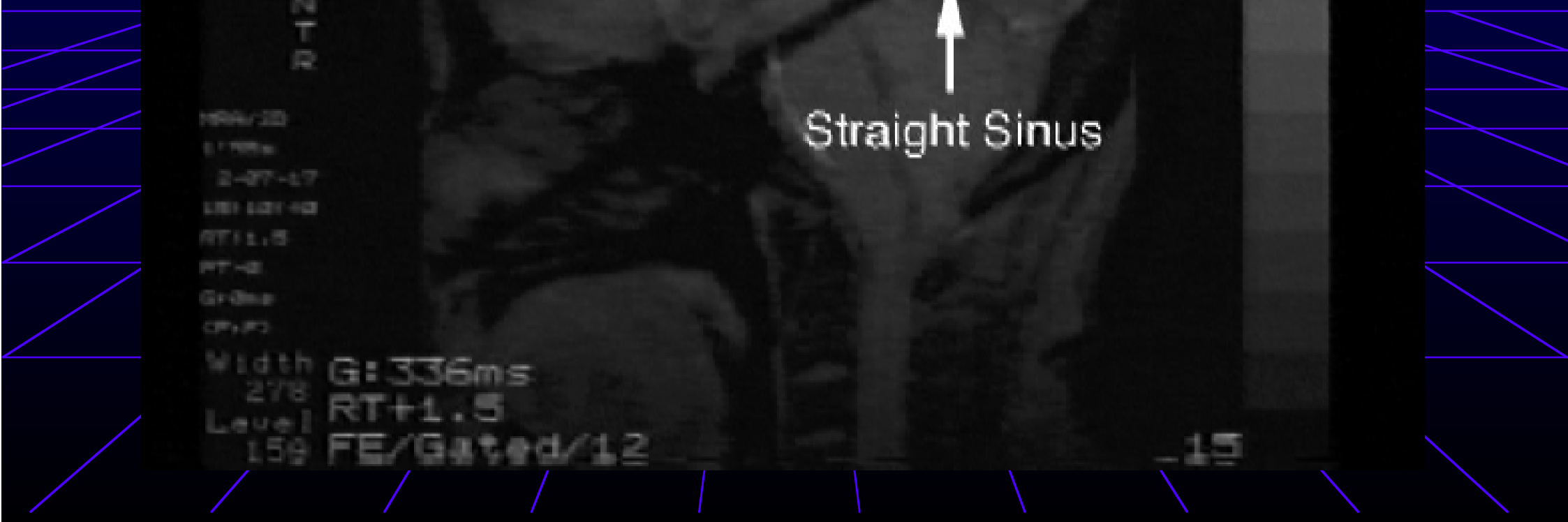
R T N A

100V/20
1.786
2-27-17
L01 L01 H0
RT+1.5
PT+0
Gr000
CP+P3

Width G:336ms
278 RT+1.5
Level FE/Gated/12
159

Superior Sagittal Sinus

Straight Sinus



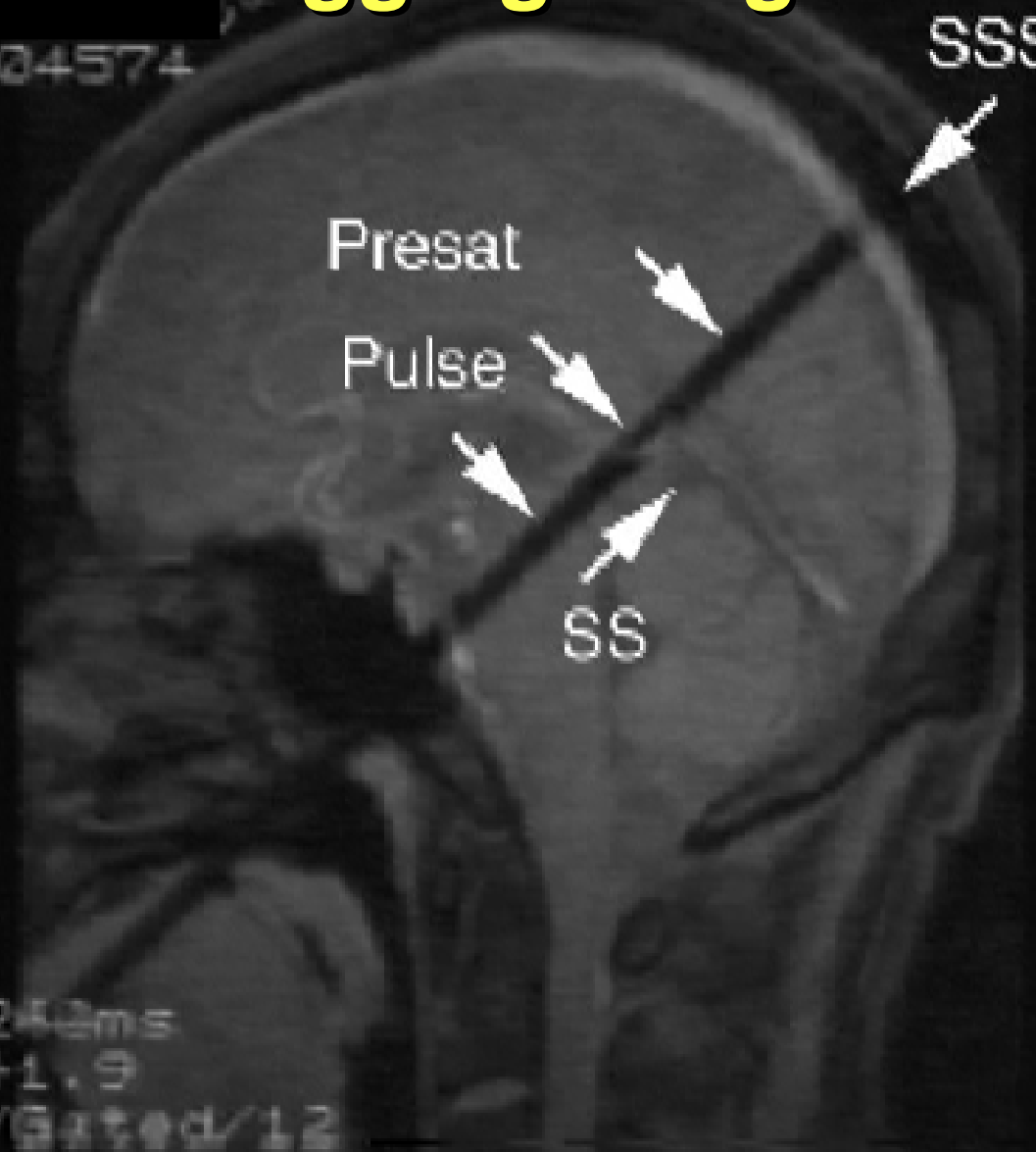
Tagging Image

M/68
978713.0
01.227
85104574
FE/208
TR=24
TE=12
FLY=182
PAT=708
SCL=608
MOC=2

R-TN-D

HRV=20
27.16s
2-27-17
L01 20184
RT+1.9
PT=0
G=0s
CP=0

Width G: 240ms
243 RT+1.9
Level FE/Gated/12



_12

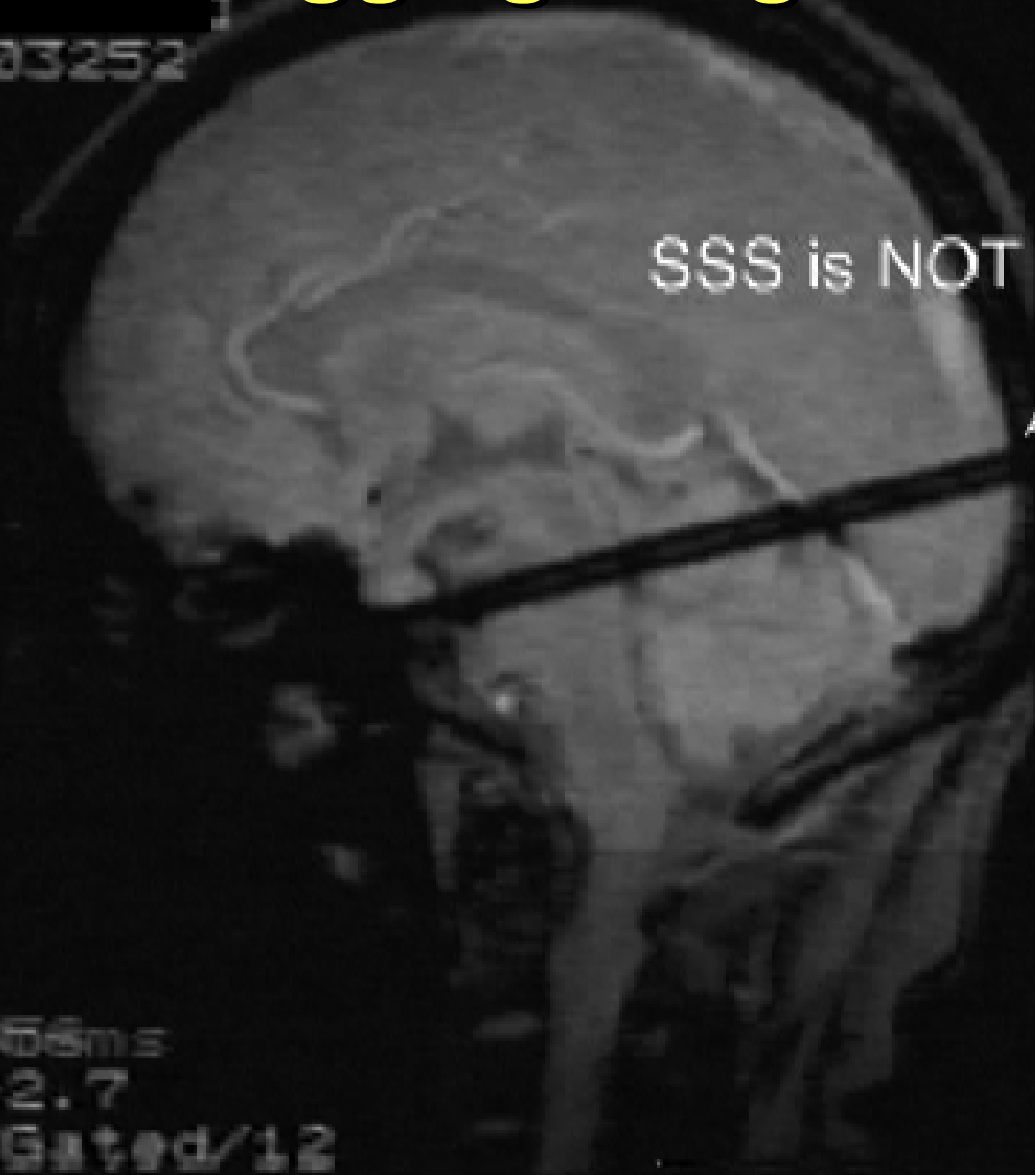Tagging Image

F/72
87003252
FE/206
TR=24
TE=12
FLY=168
PAT=705
SCD=605
MOC=2

RTN/A

HRV=20
2176
2-07-16
LBI=11148
RT=2.7
PT=0
G=0
CP=0

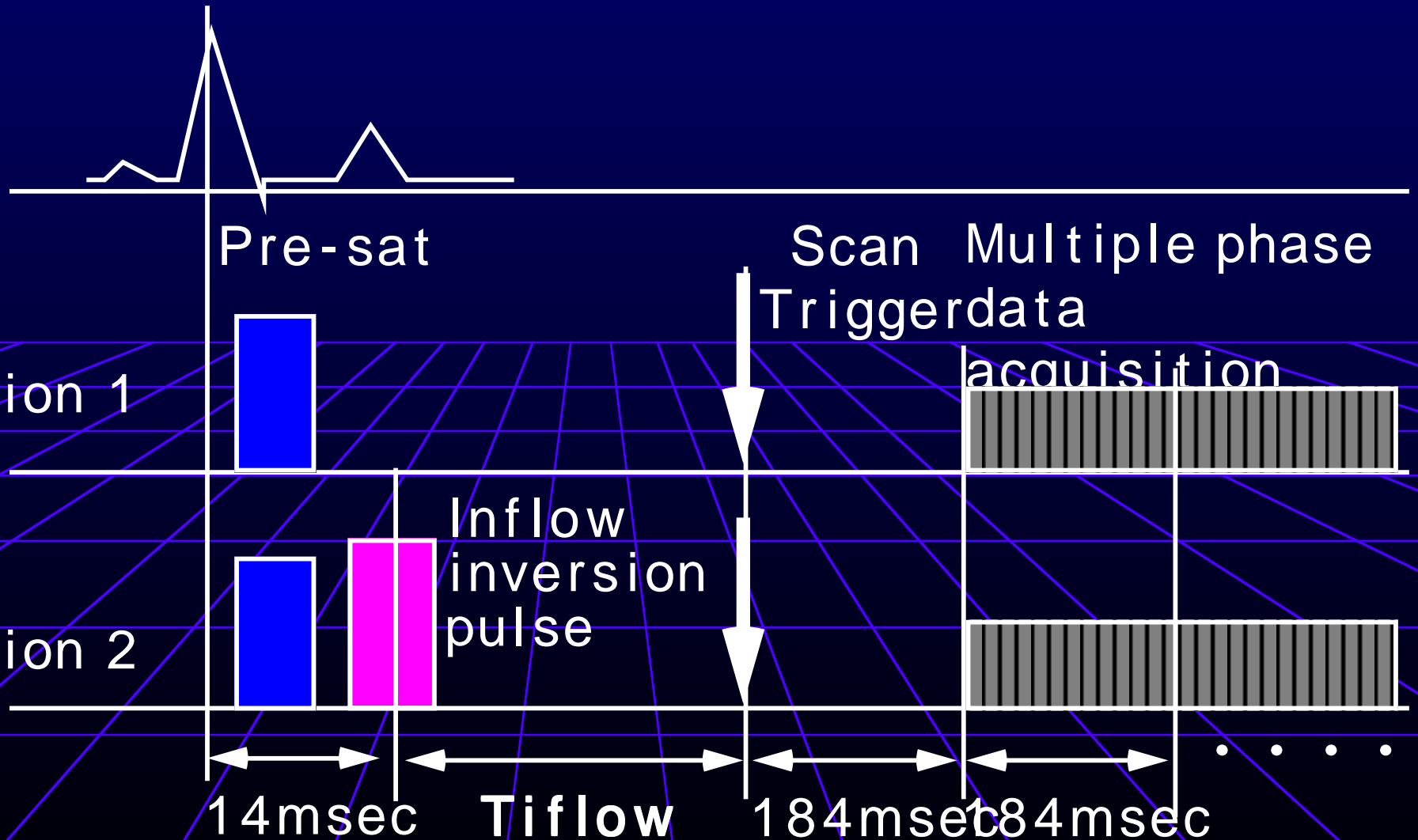
Width G: 455ms
191 RT+2.7
Level 144 FE/Gated/12



SSS is NOT Visualized

STAR

R-wave

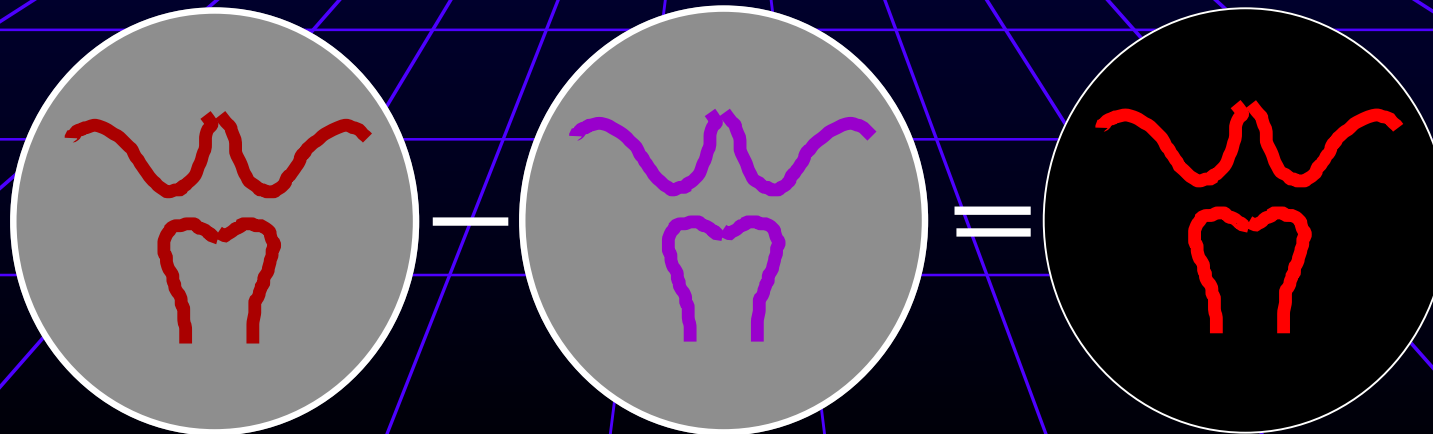
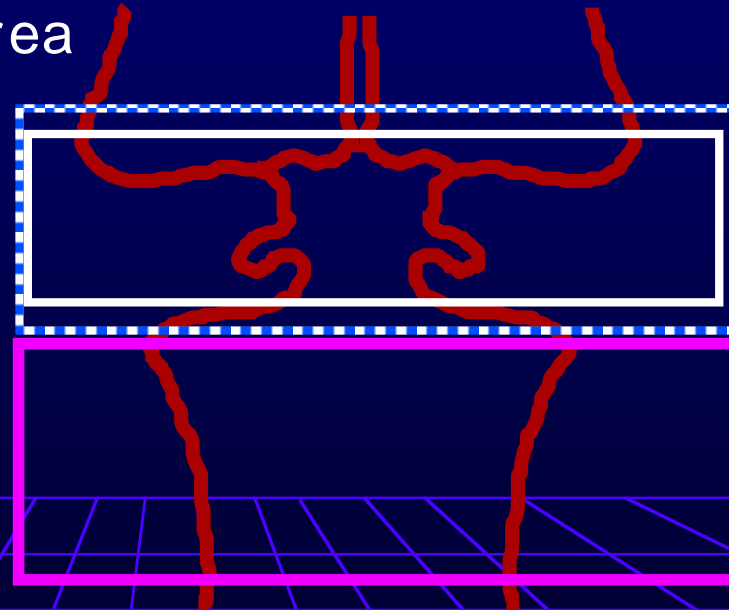


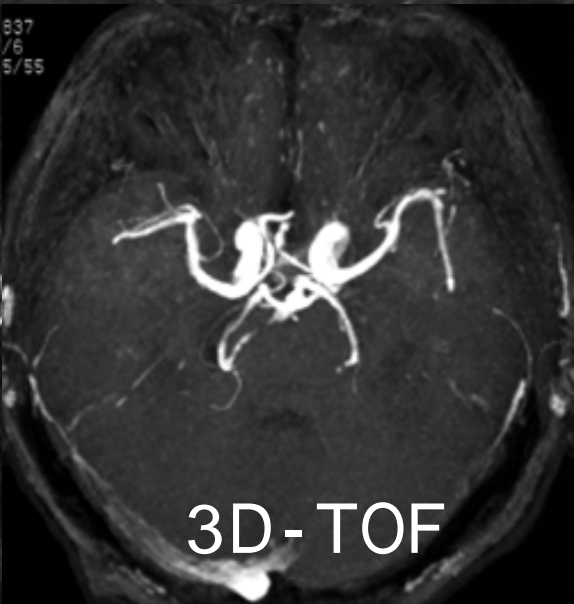
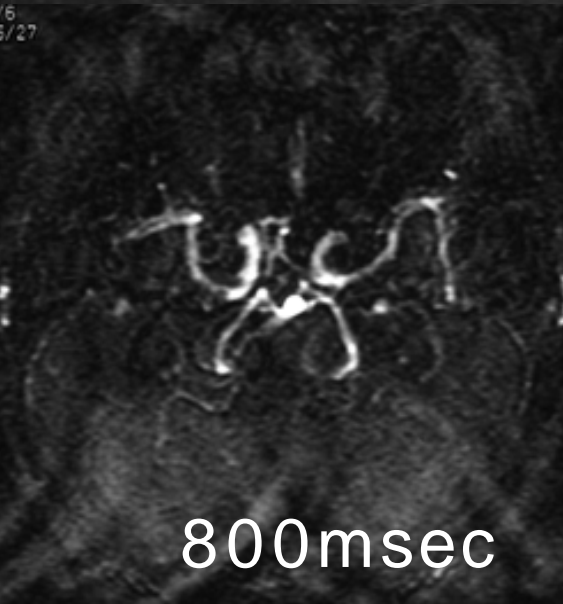
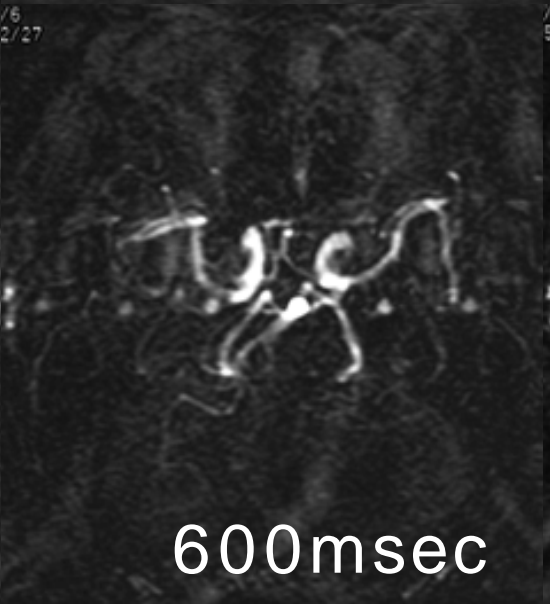
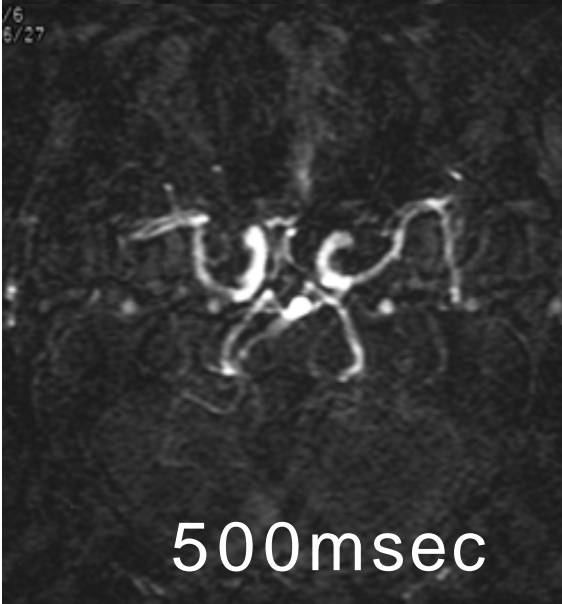
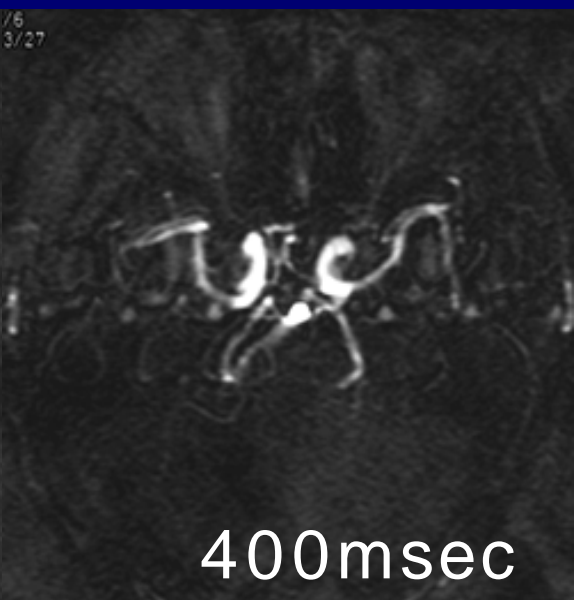
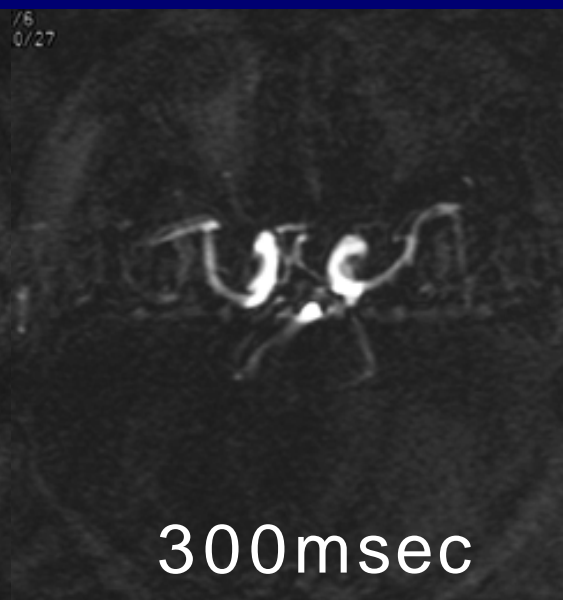
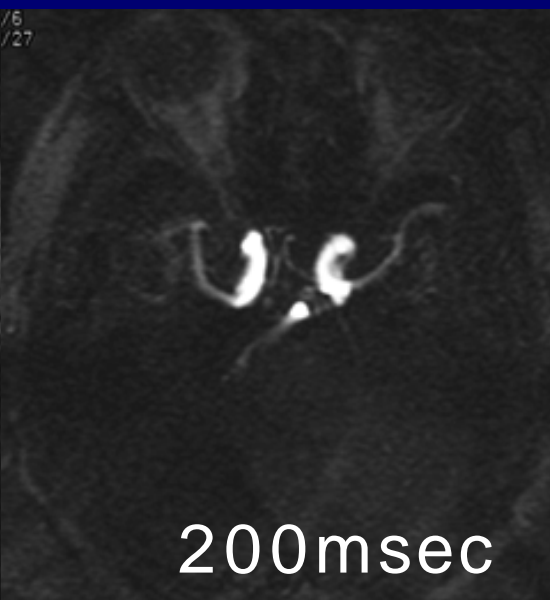
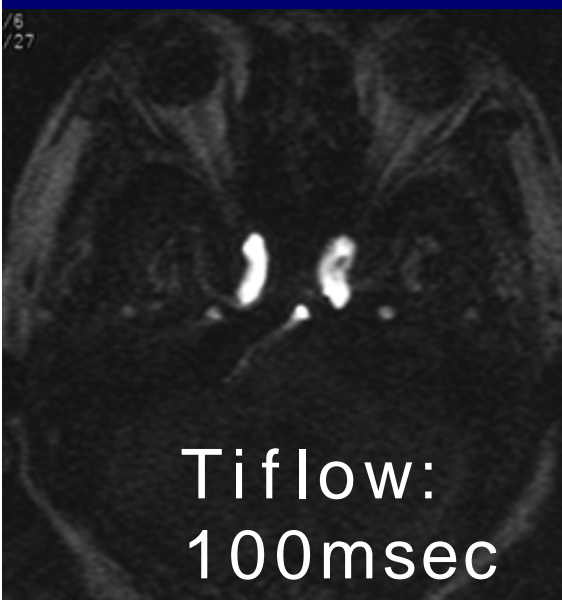
STAR

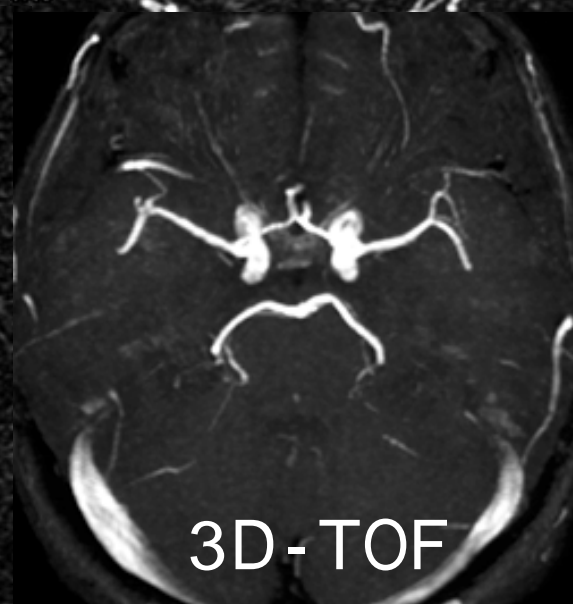
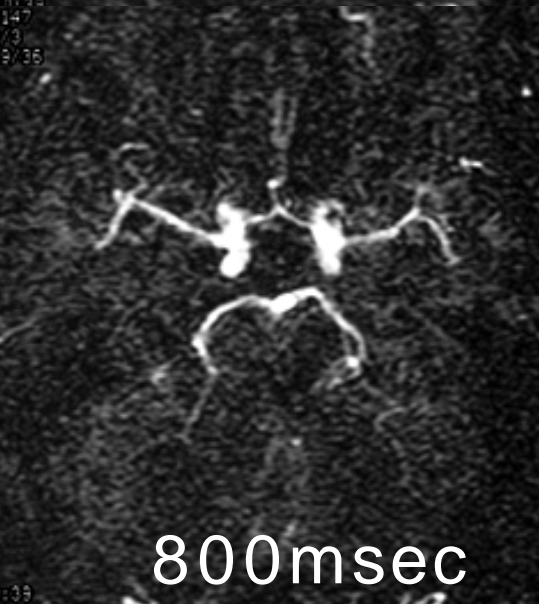
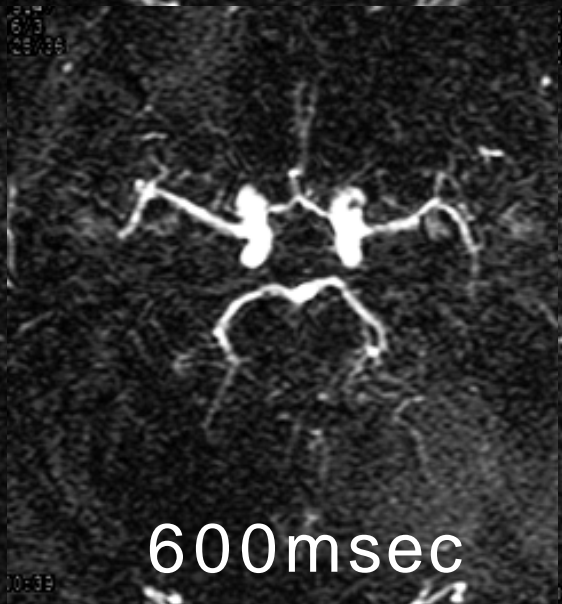
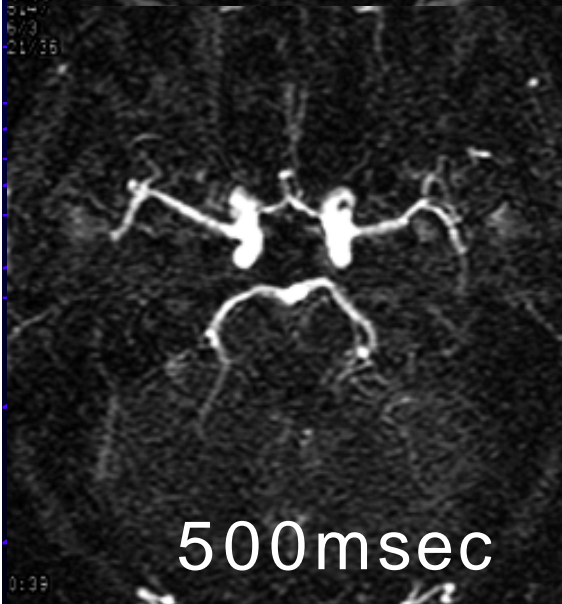
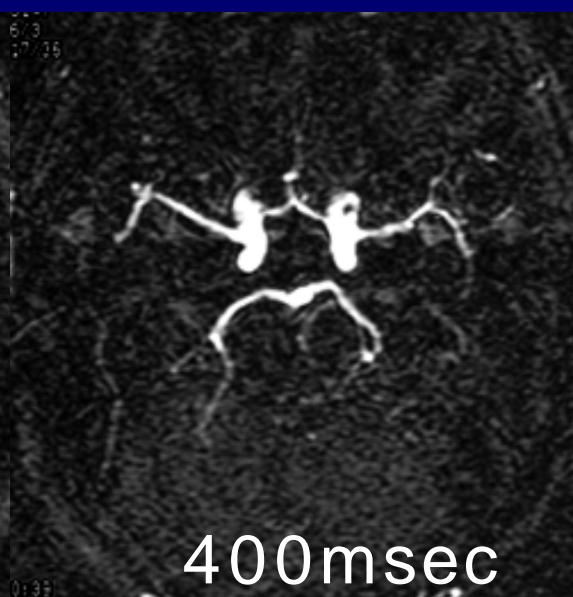
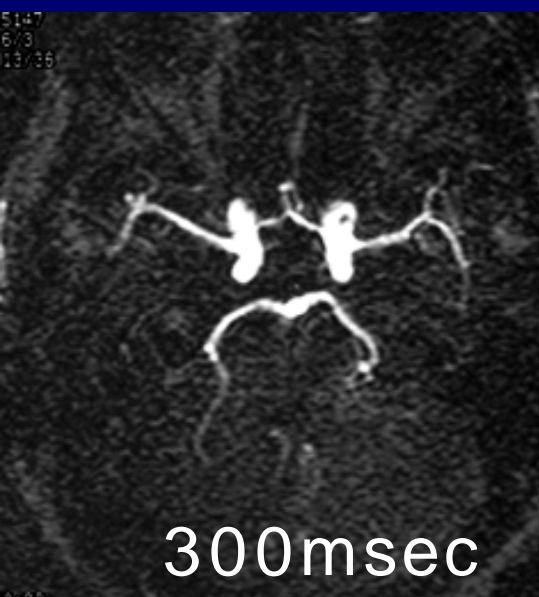
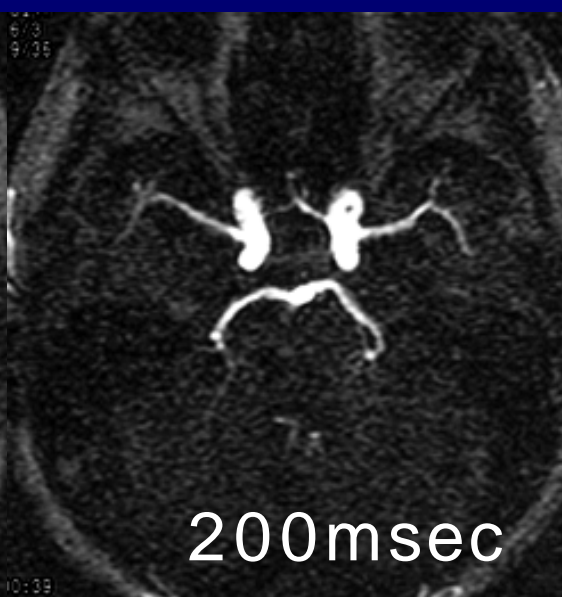
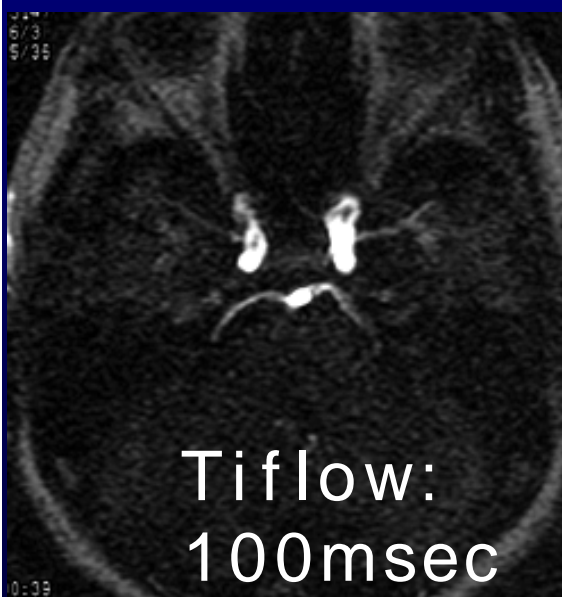
Pre-saturation area

Scan slice

Inflow slab inversion







1/6
7/23

5402
7/6
5/23

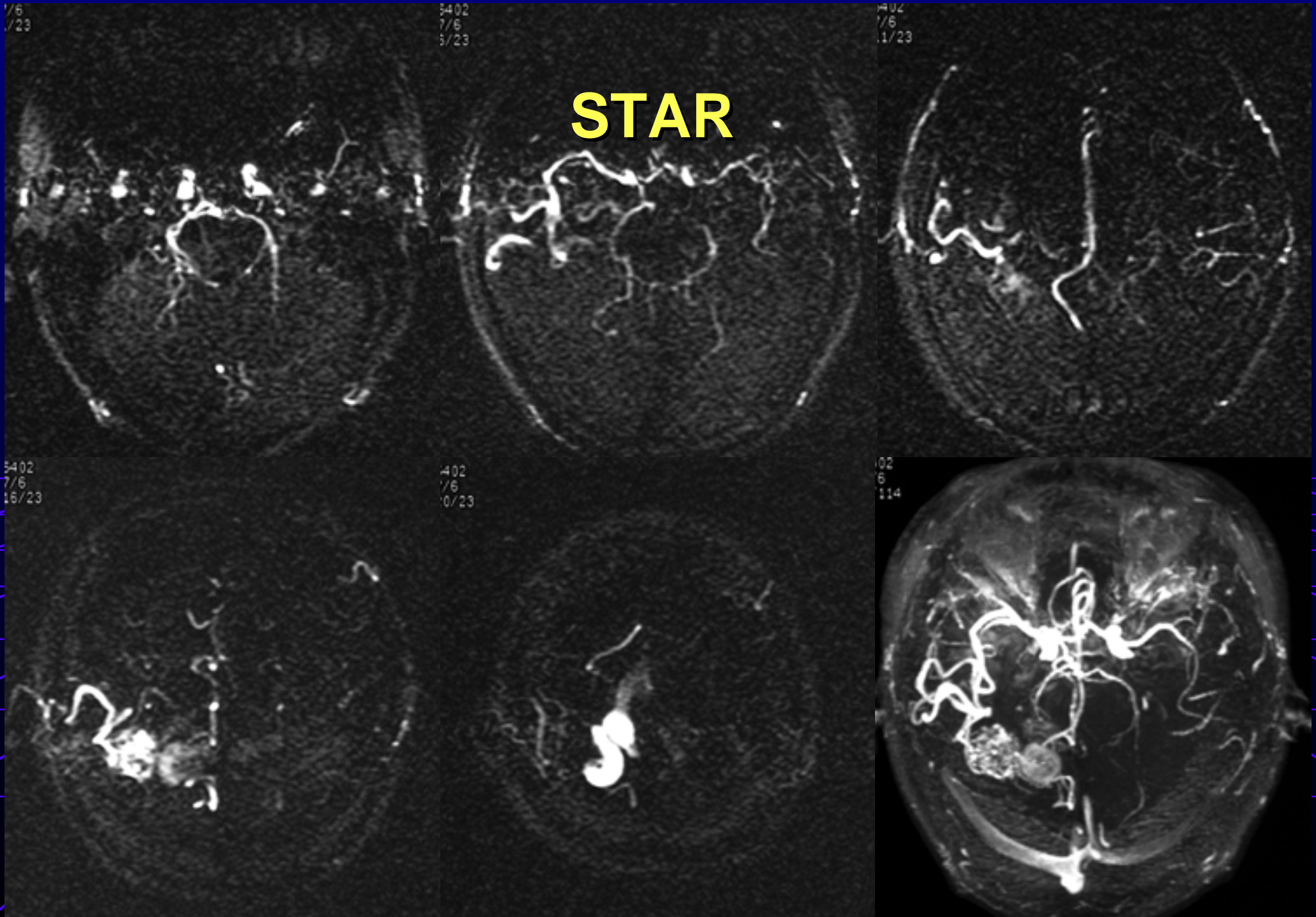
402
7/6
11/23

STAR

5402
7/6
16/23

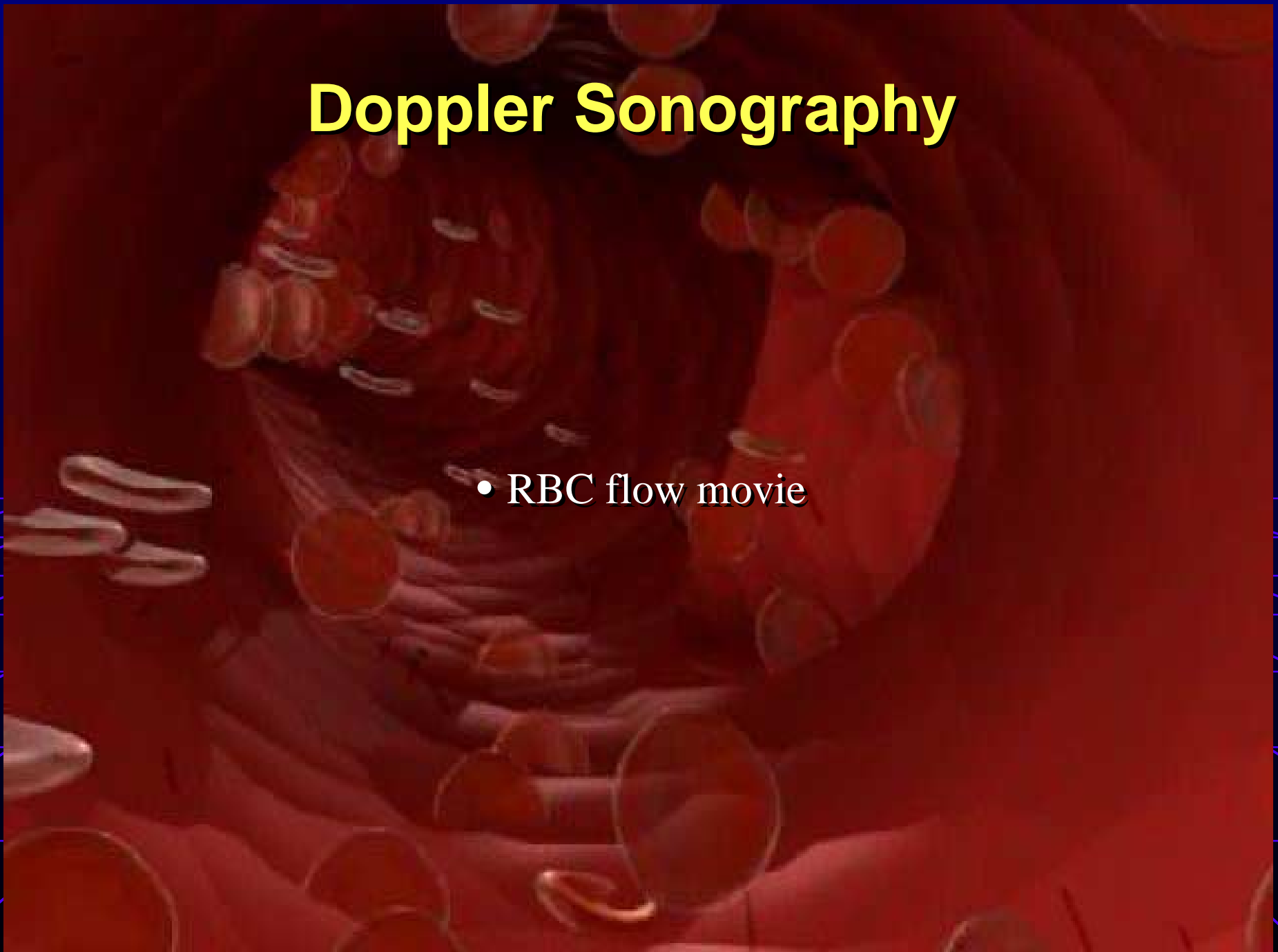
402
7/6
10/23

402
6
114



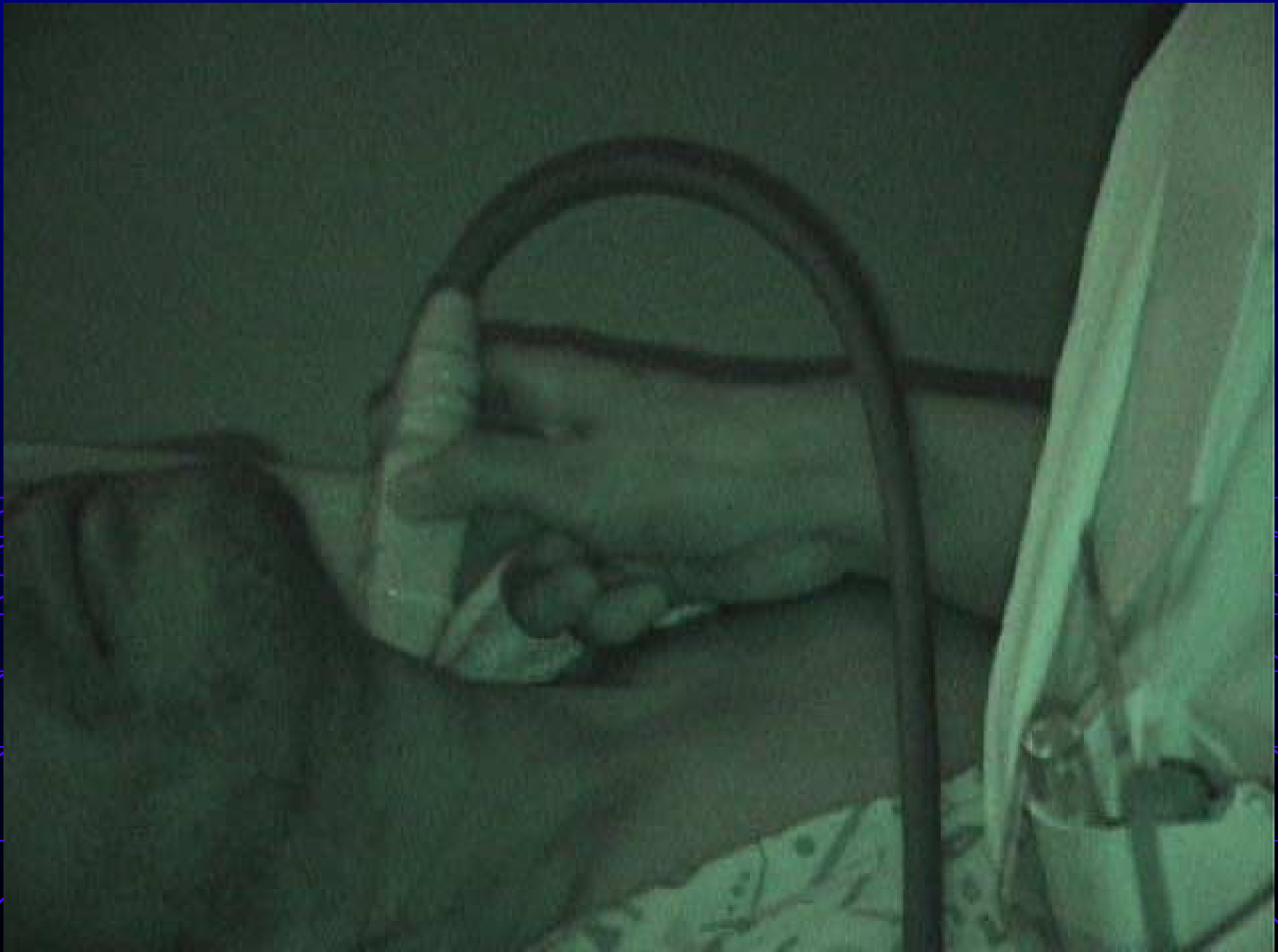Doppler Sonography

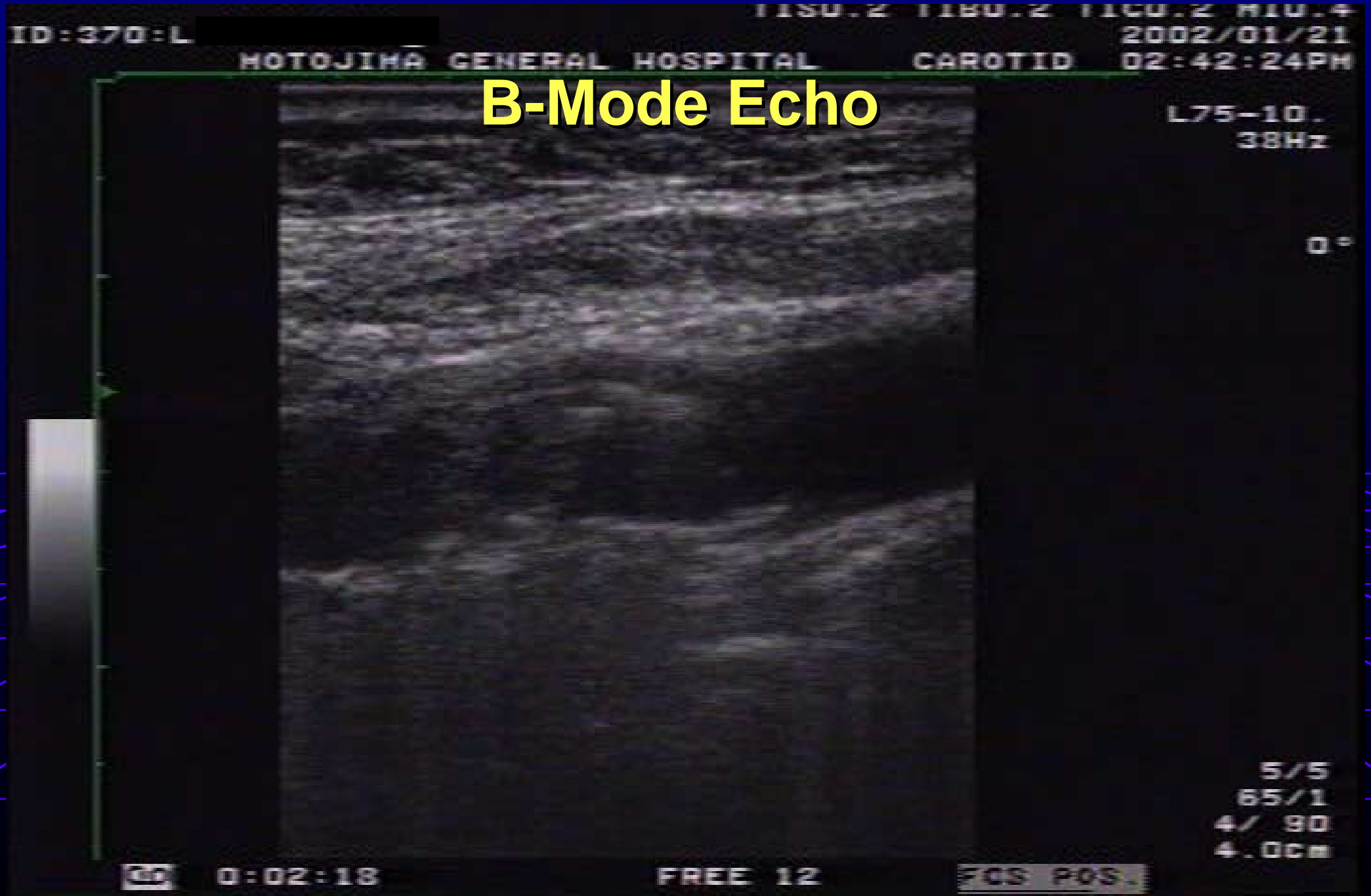- RBC flow movie



Body Surface Echo (Carotid Echo)

- B Mode
- Doppler
- Power Doppler





ID:370:L

T1S0.2 T1R0.2 T1C0.4 R10.6

HOTOJIHA GENERAL HOSPITAL

CAROTID

2002/01/21

02:42:53PM


Colour Doppler

L75-10.
10Hz

P12.0k

0°

18.2



18.2

5/4



28/20
1/0
5/5
65/1
4/ 90
4.0cm



0:02:47

FREE 12

POS.


C.Z. SFT

ID:370:L HOTOJIMA GENERAL HOSPITAL CAROTID 2002/01/21 02:42:43PM

Power Doppler

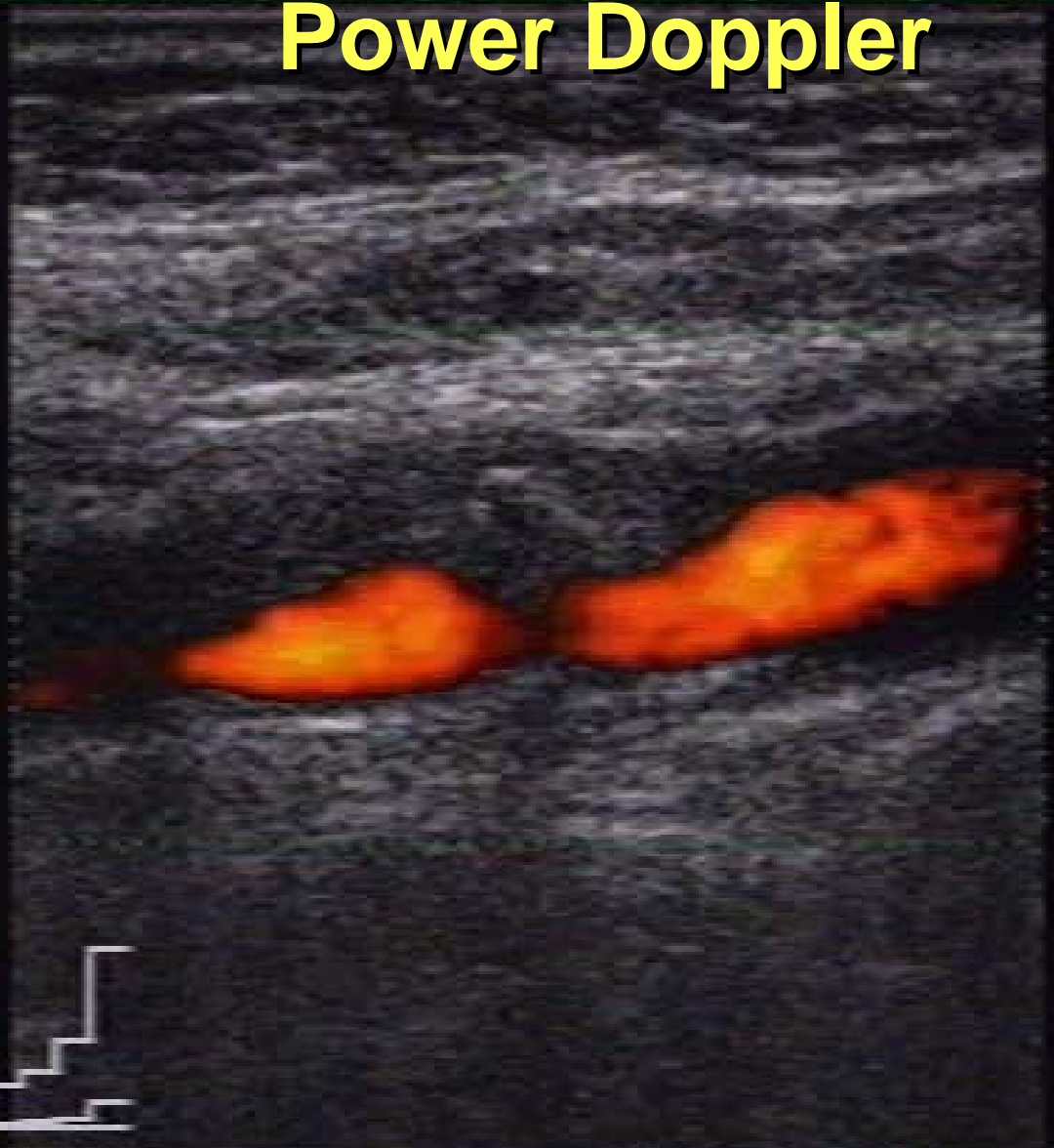L75-10.
10Hz
P12.0k
0°

30
10.9
3/3

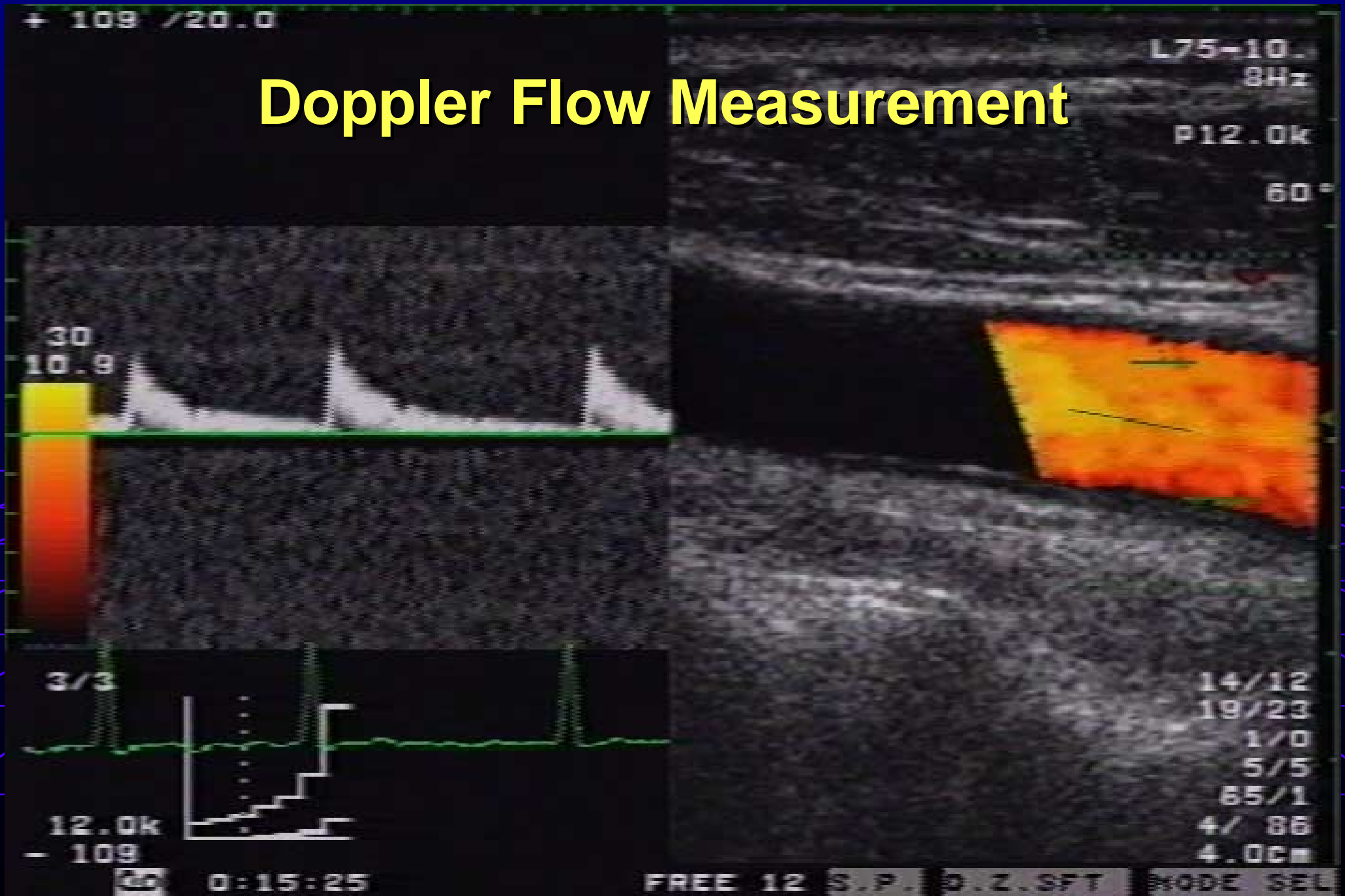


19/23
1/0
5/5
65/1
4/ 90
4.0cm

0:02:36 FREE 12 POS. C.Z.SFT

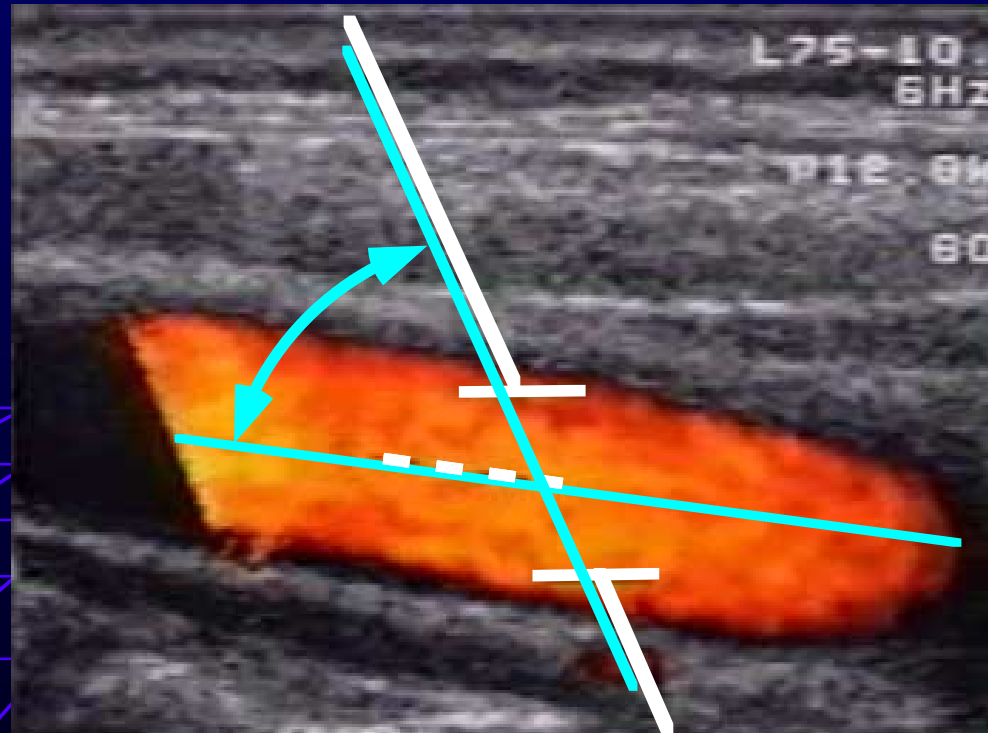


Doppler Flow Measurement



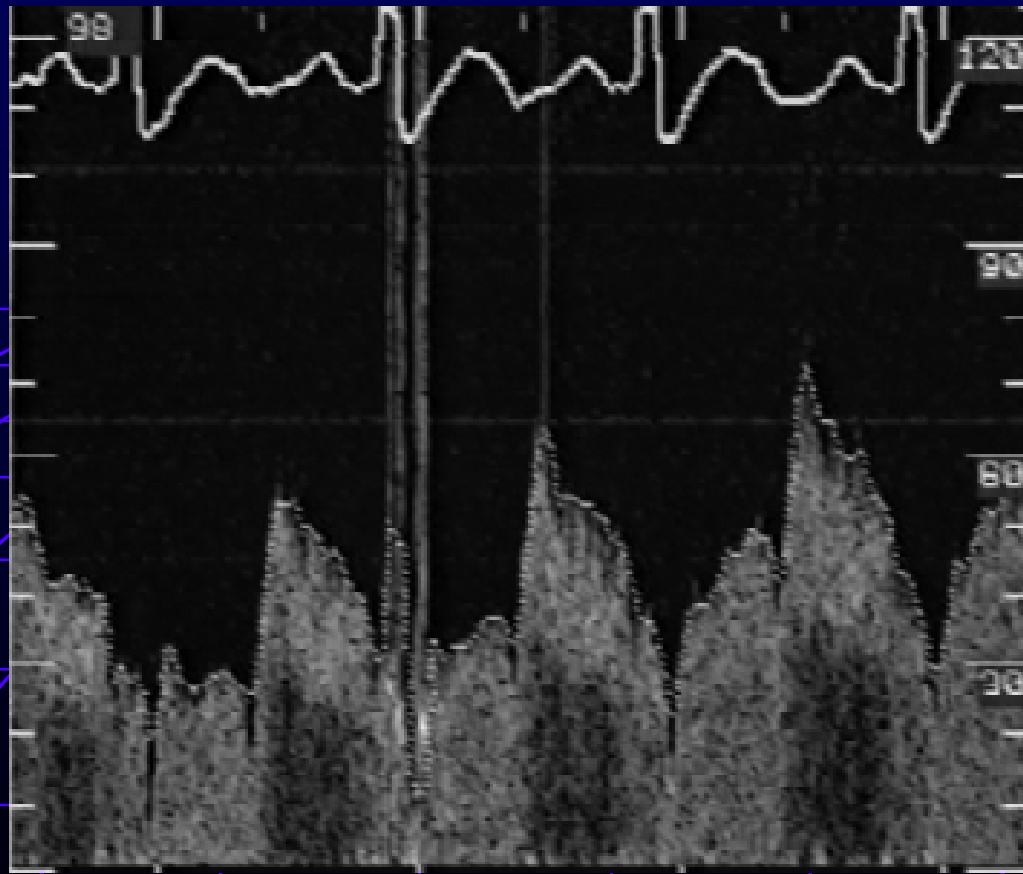
Doppler Flow Measurement

- velocity measure




	=	30 °	60 °
Error in Angulation = 1 °		1 %	3 %
Error in Angulation = 5 °		5 %	15 %

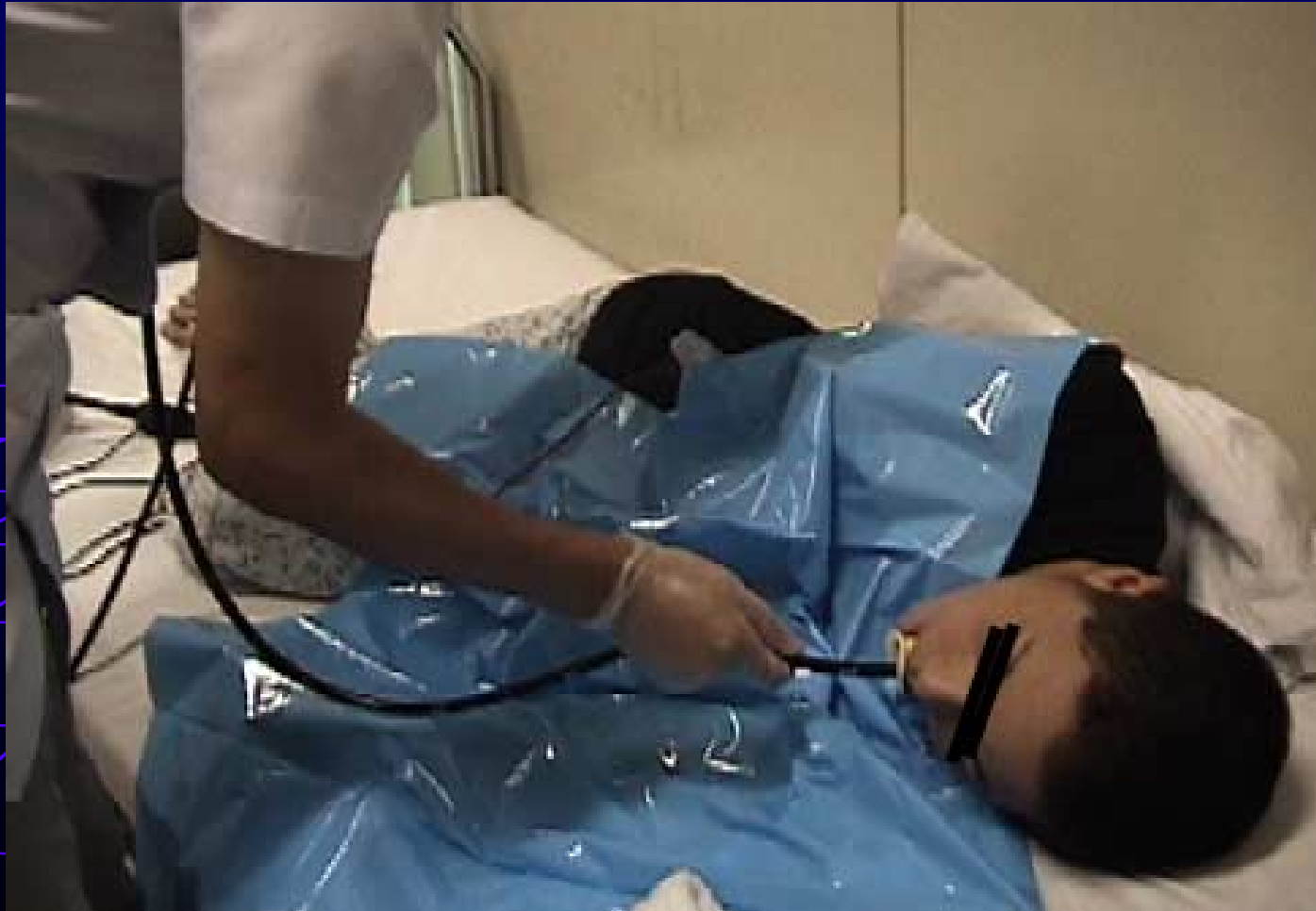HITS



Trans-Esophageal Echo



Trans-Esophageal Echo



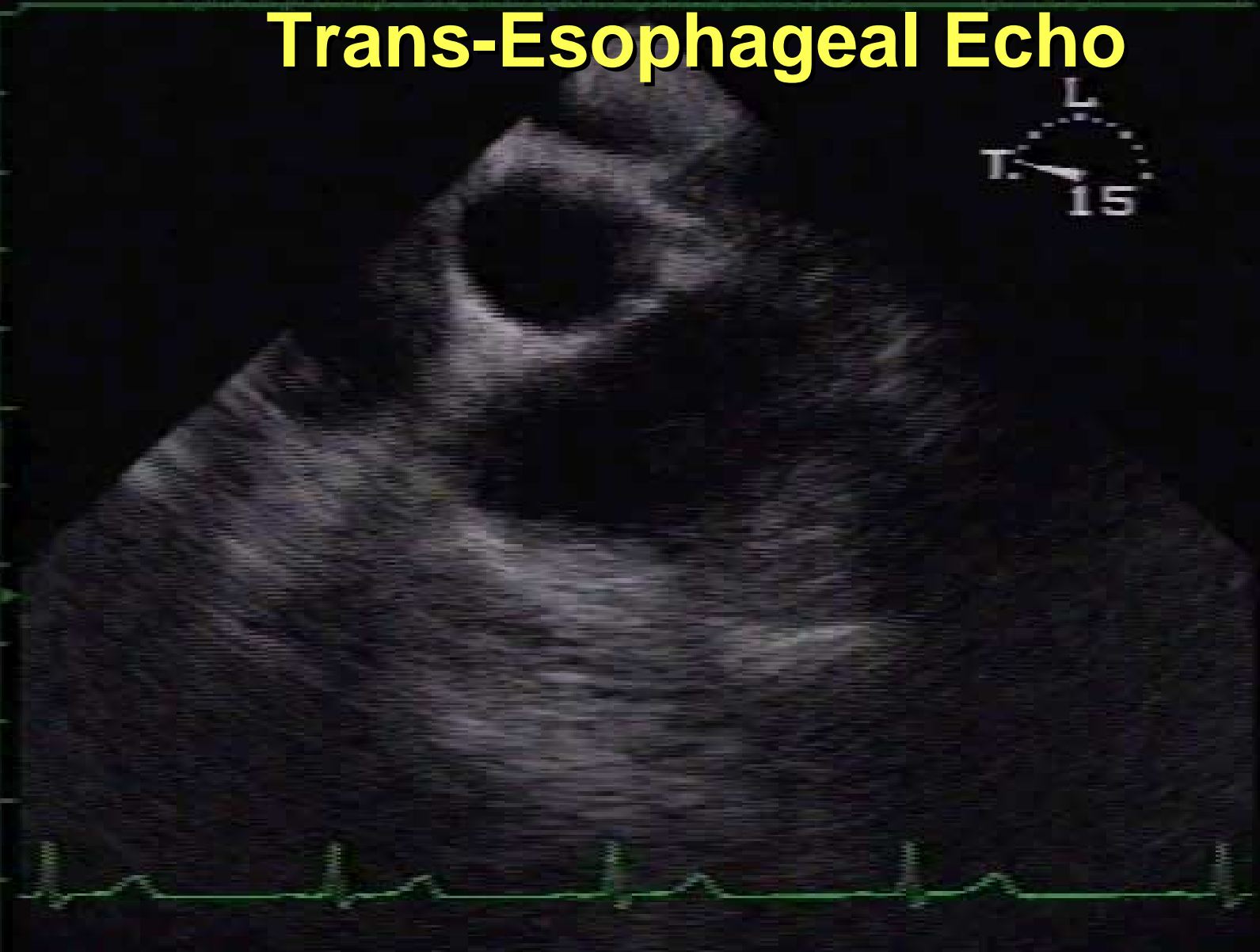

ID:14041: T1S0.4 T1B0.4 T1C0.4 R10.6
HOTOJIMA GENERAL HOSPITAL H-TEE 65 2002/07/18
09:48:32AM

Trans-Esophageal Echo

S50-5.0
84Hz



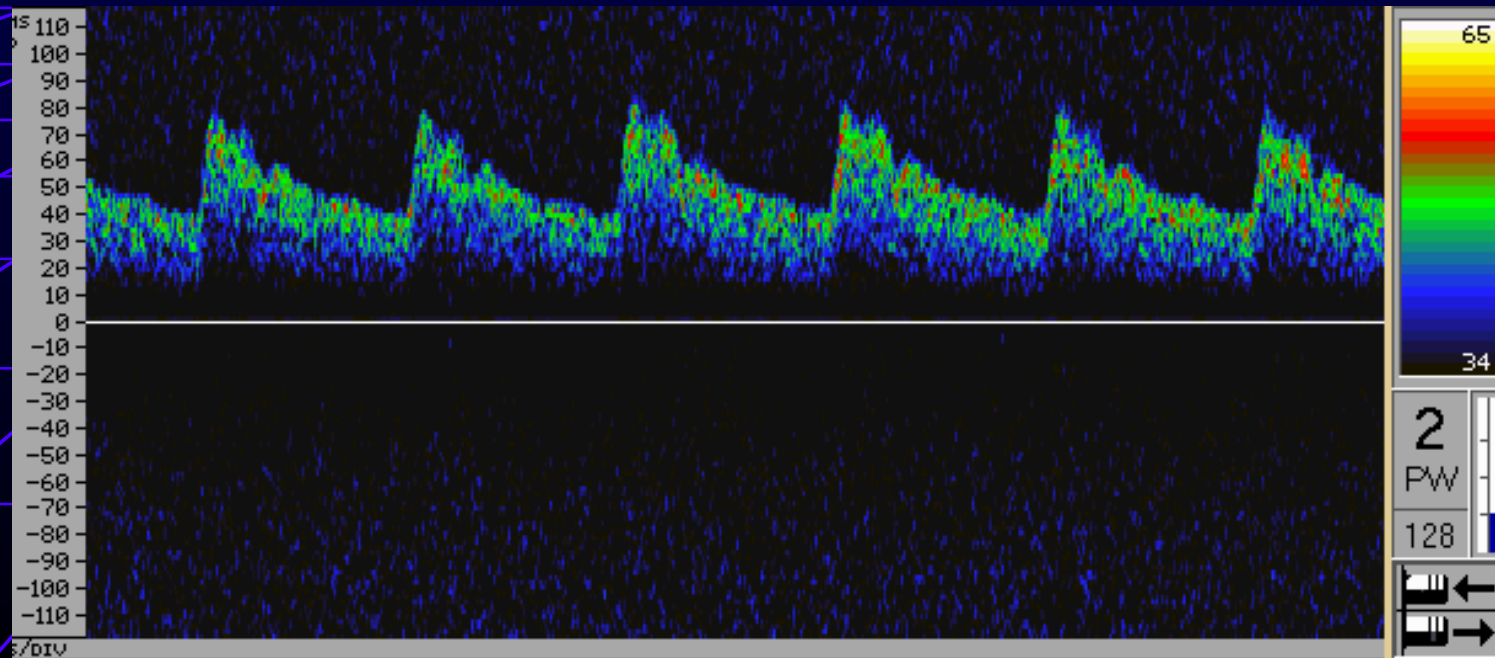
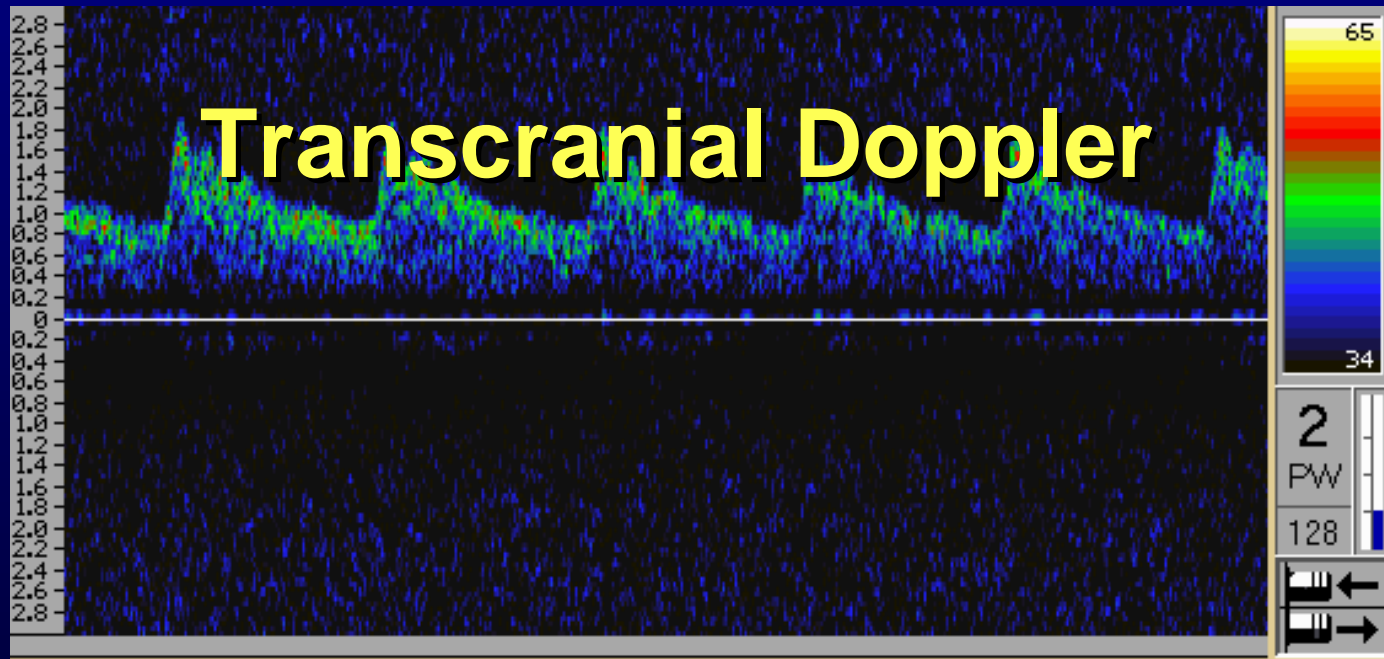
23°



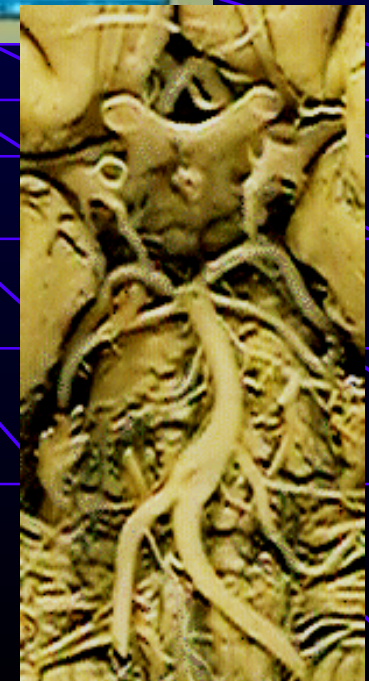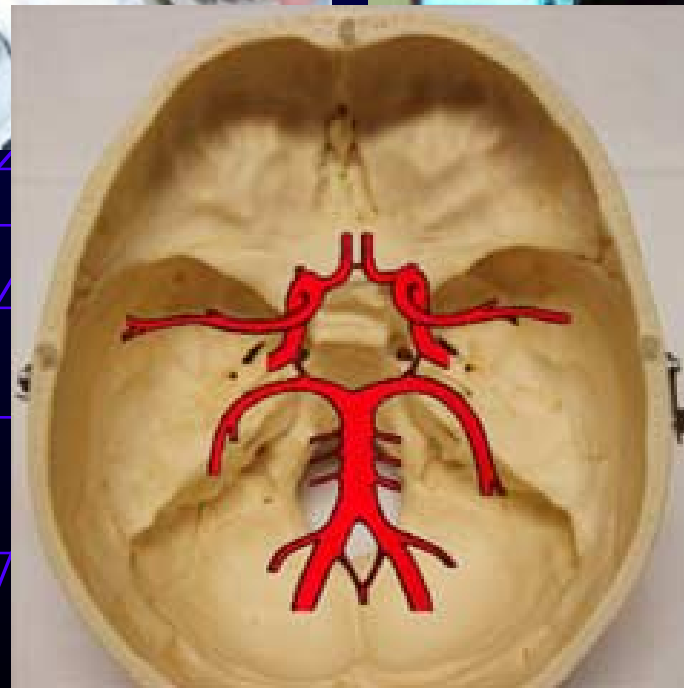

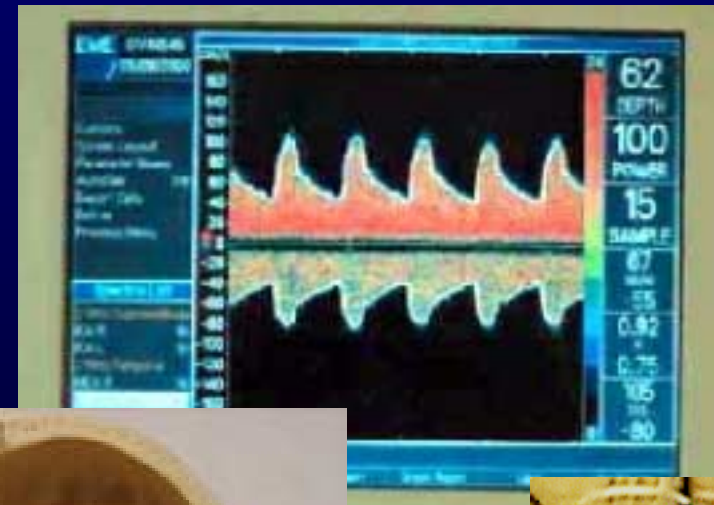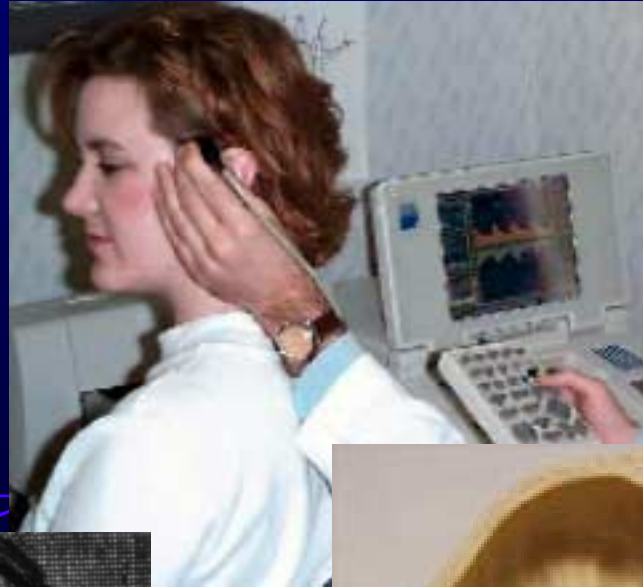1/0
50/0
4/ 36
12.0cm

0:04:29

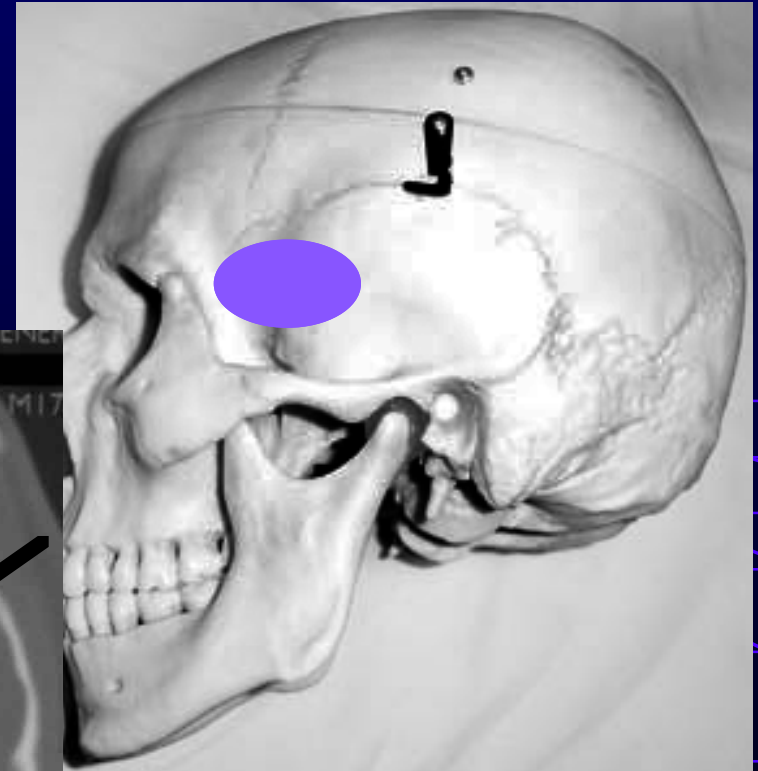
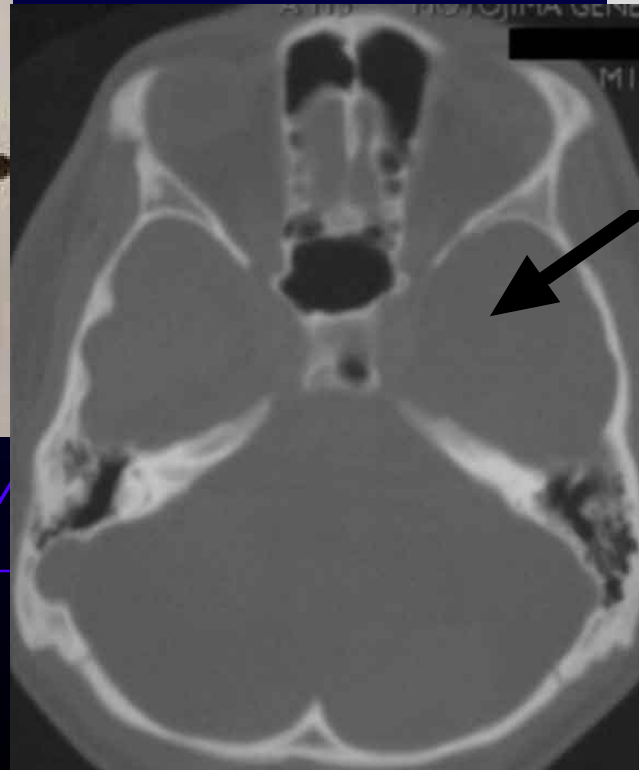
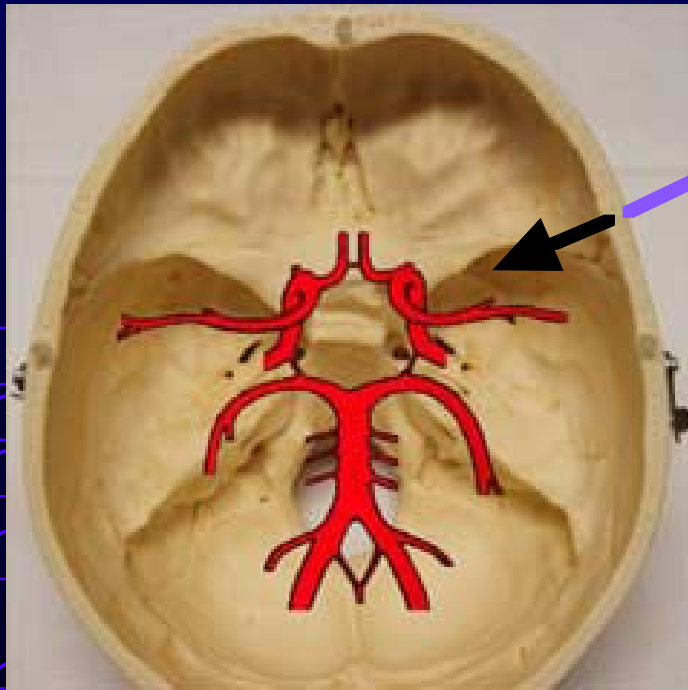
FCS POS.



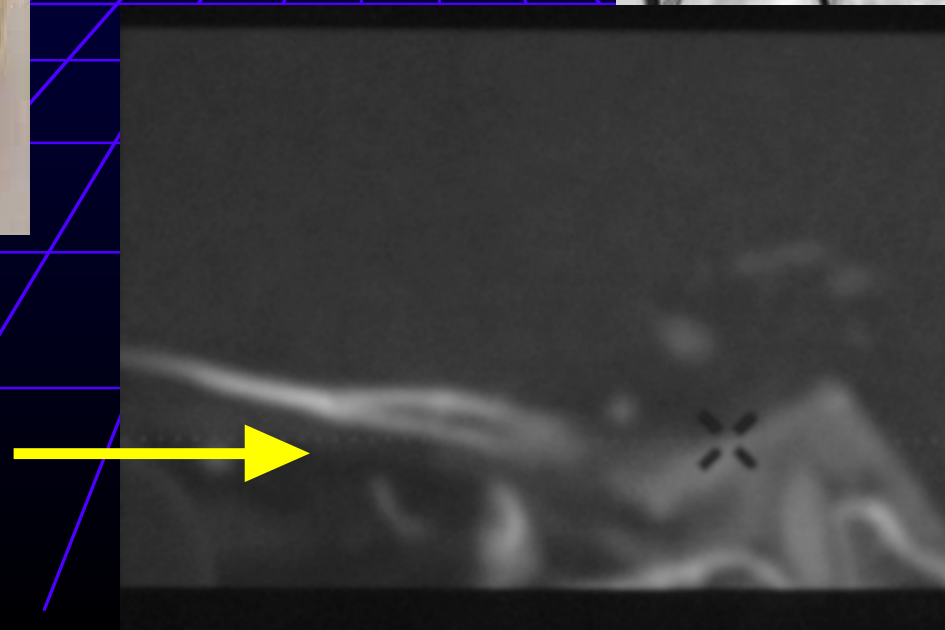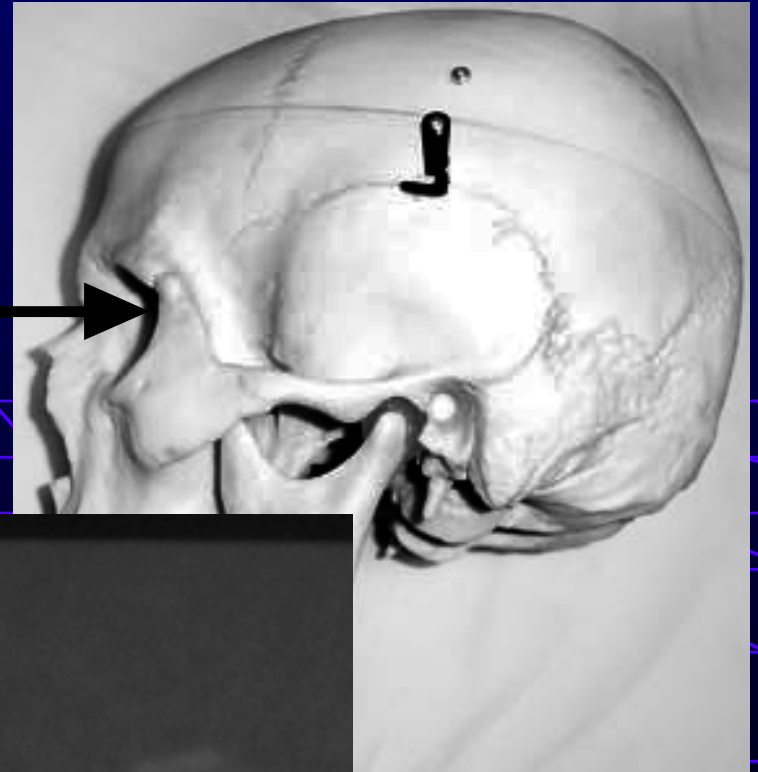
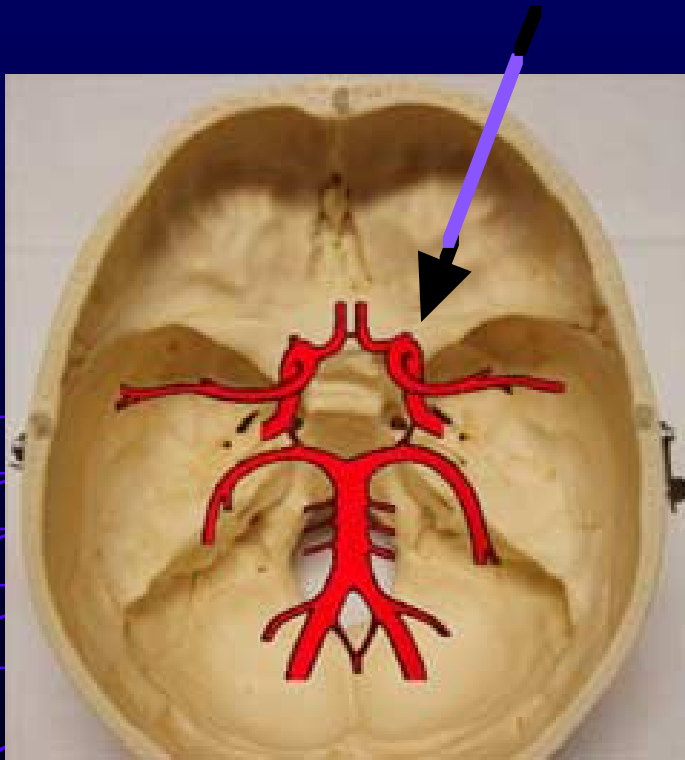
Transcranial Doppler



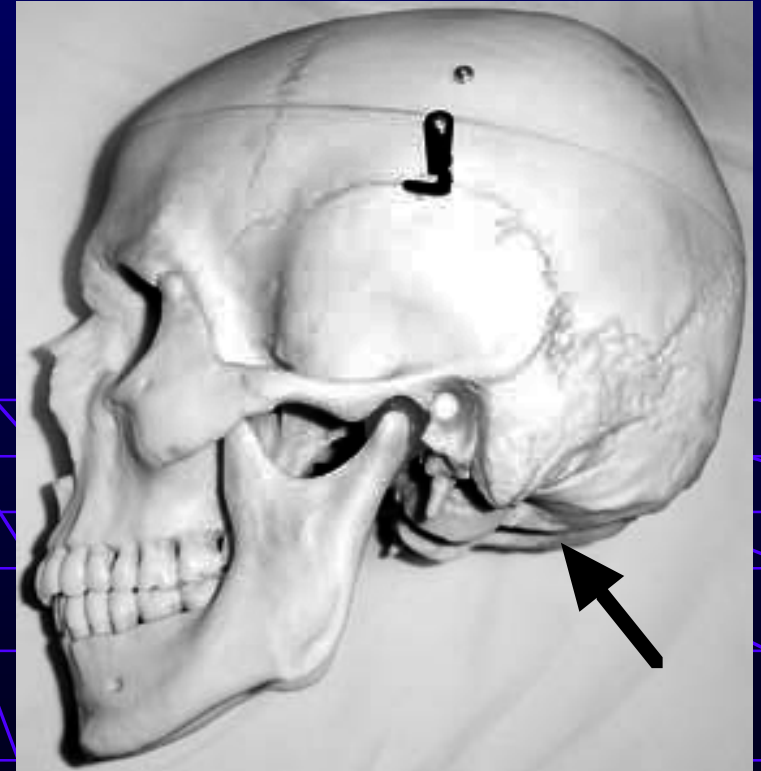
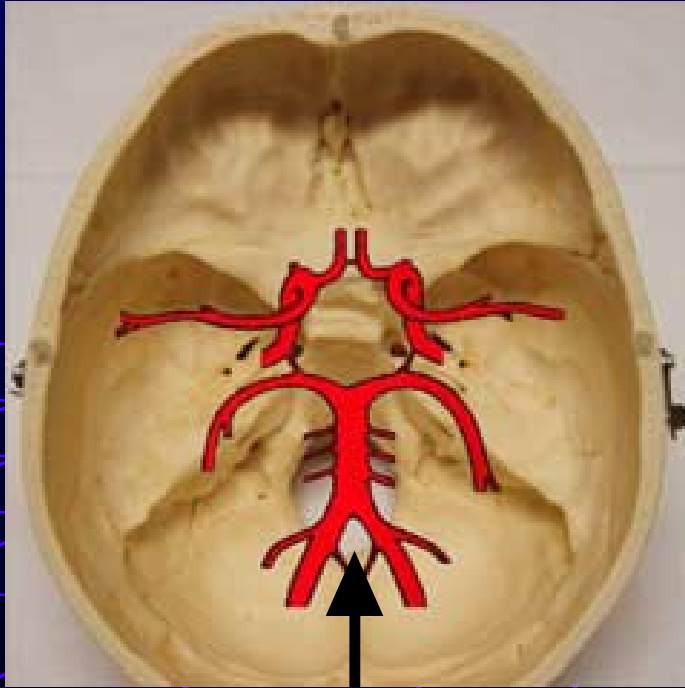
Trans-Cranial Doppler



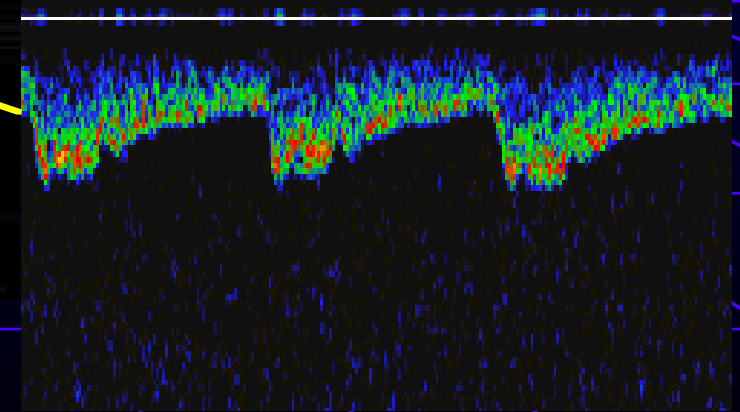
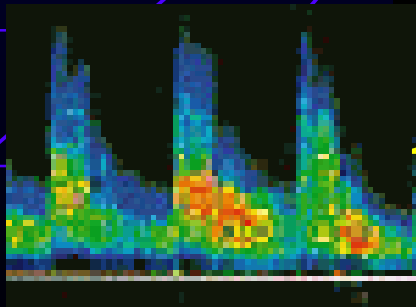
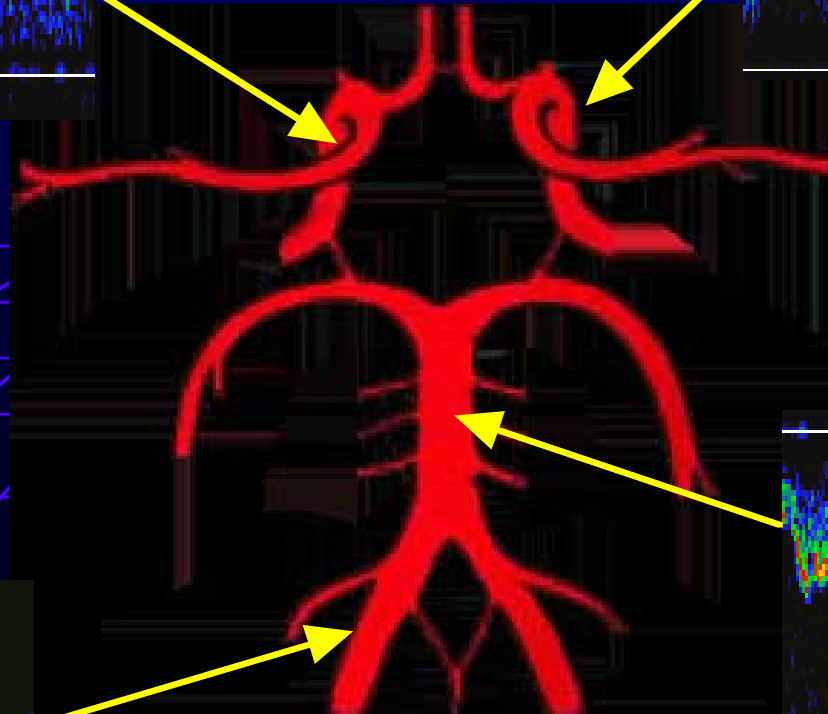
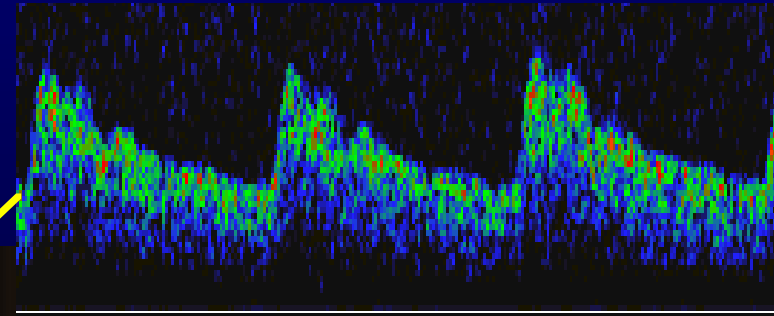
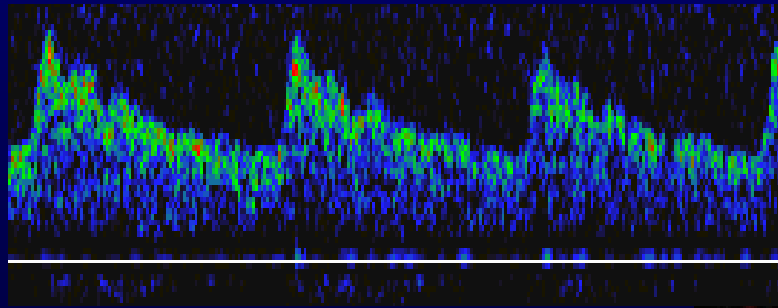
Transcranial Doppler



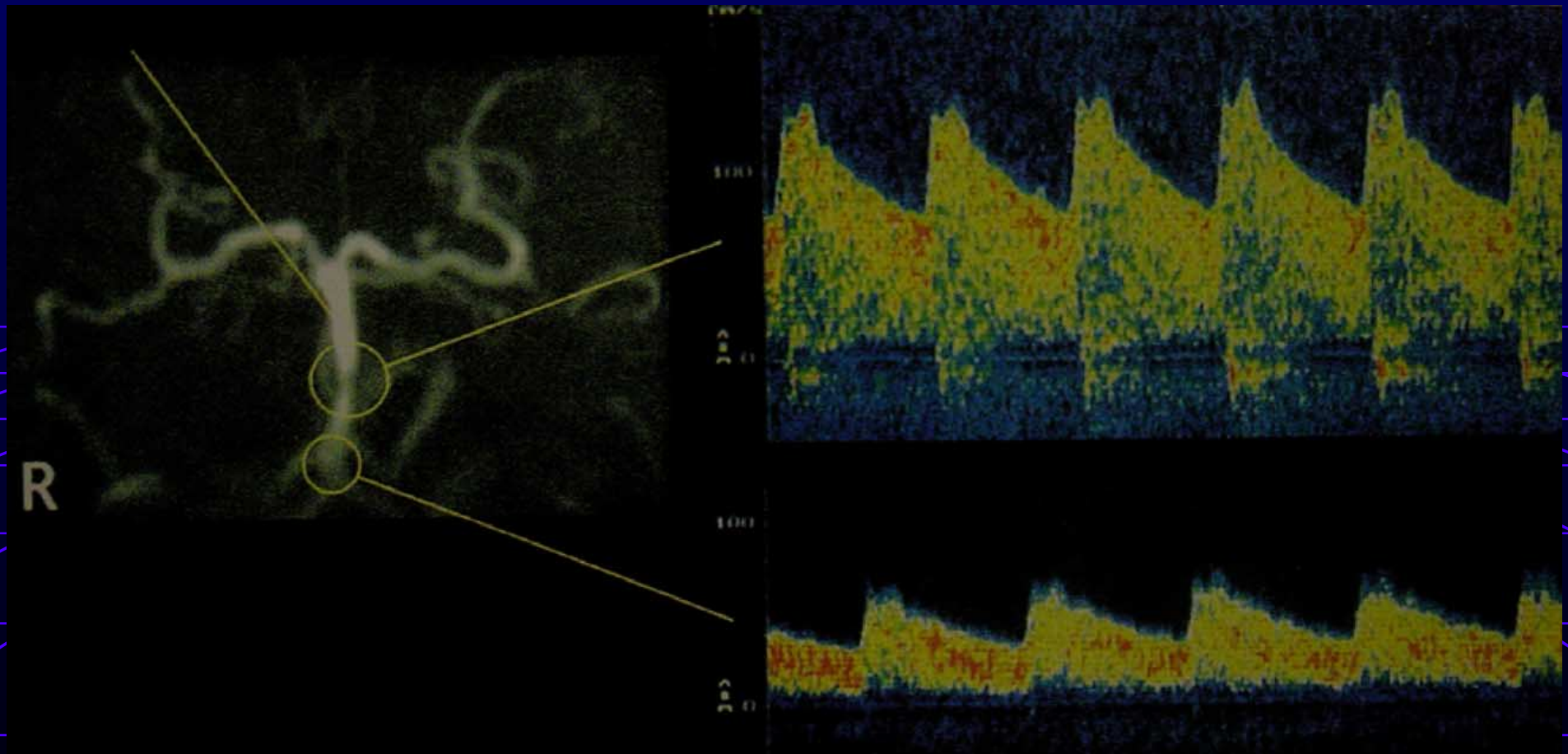
Trans-Cranial Doppler



Transcranial Doppler

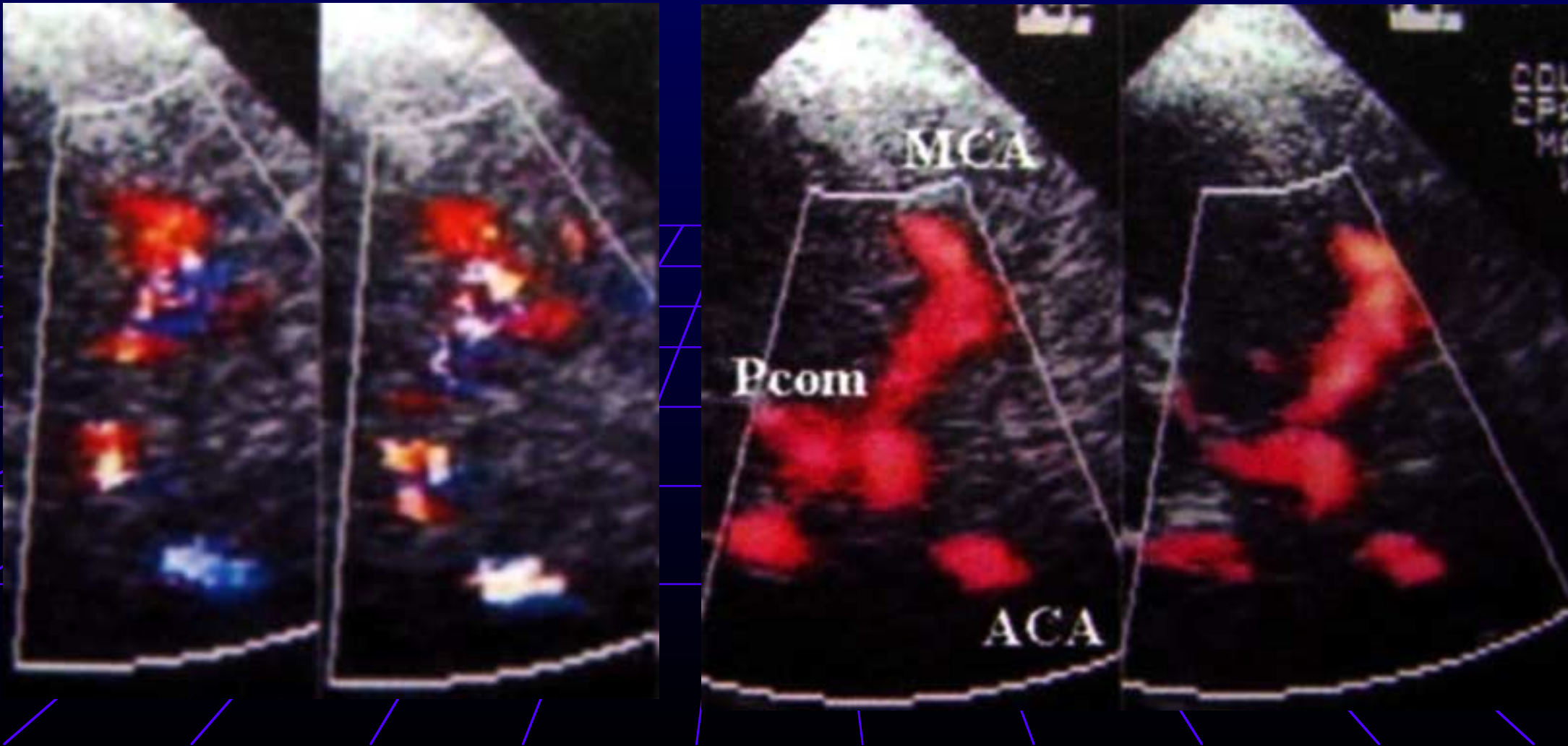


Transcranial Doppler



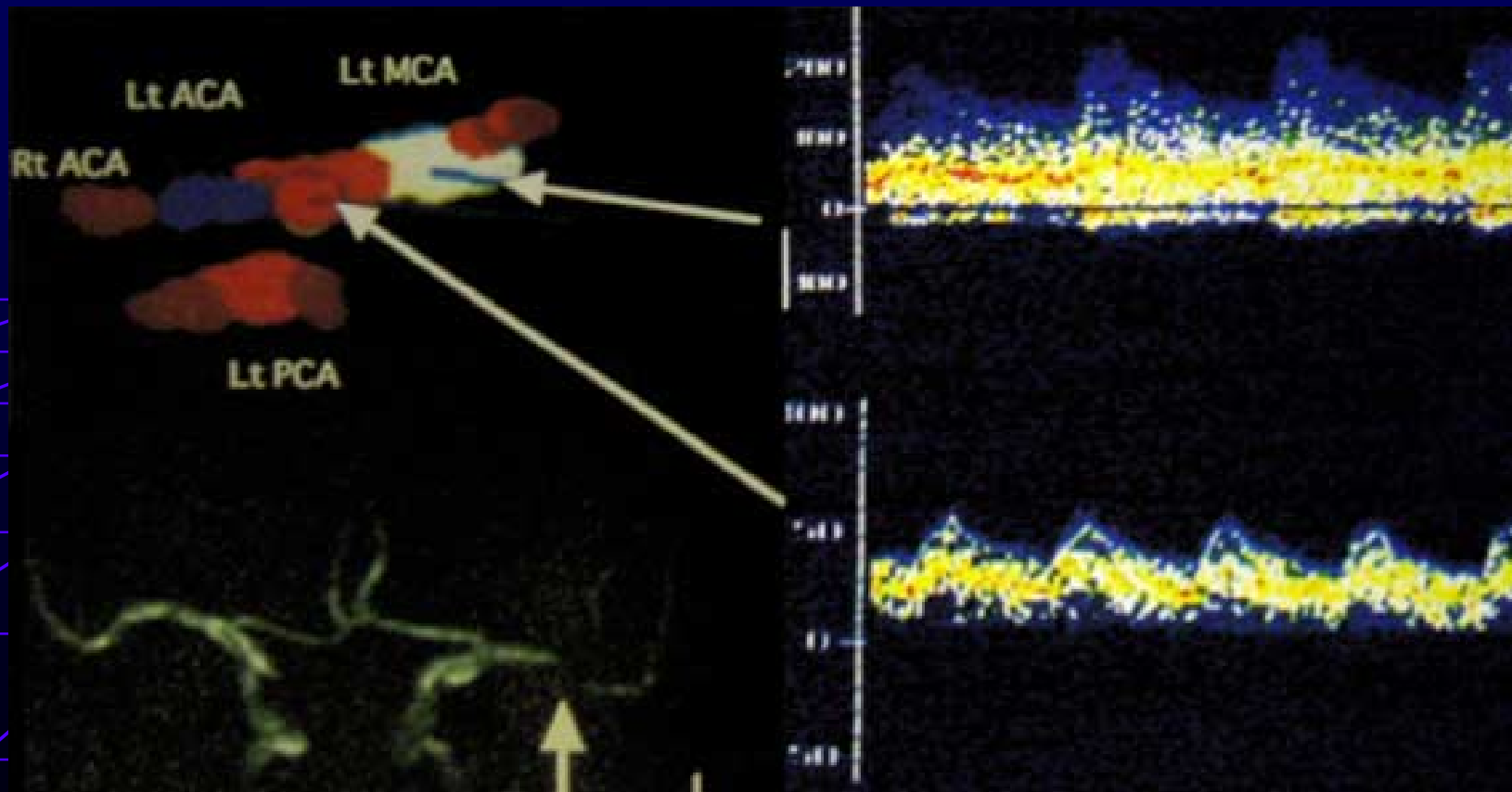
TDC Valiation - I

- Transcranial Colour Flow Imaging
- Contrast material for echo

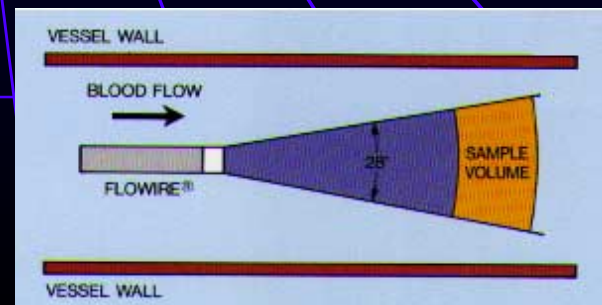
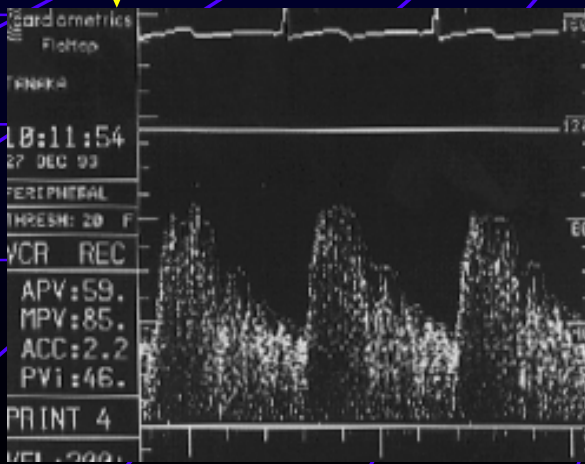
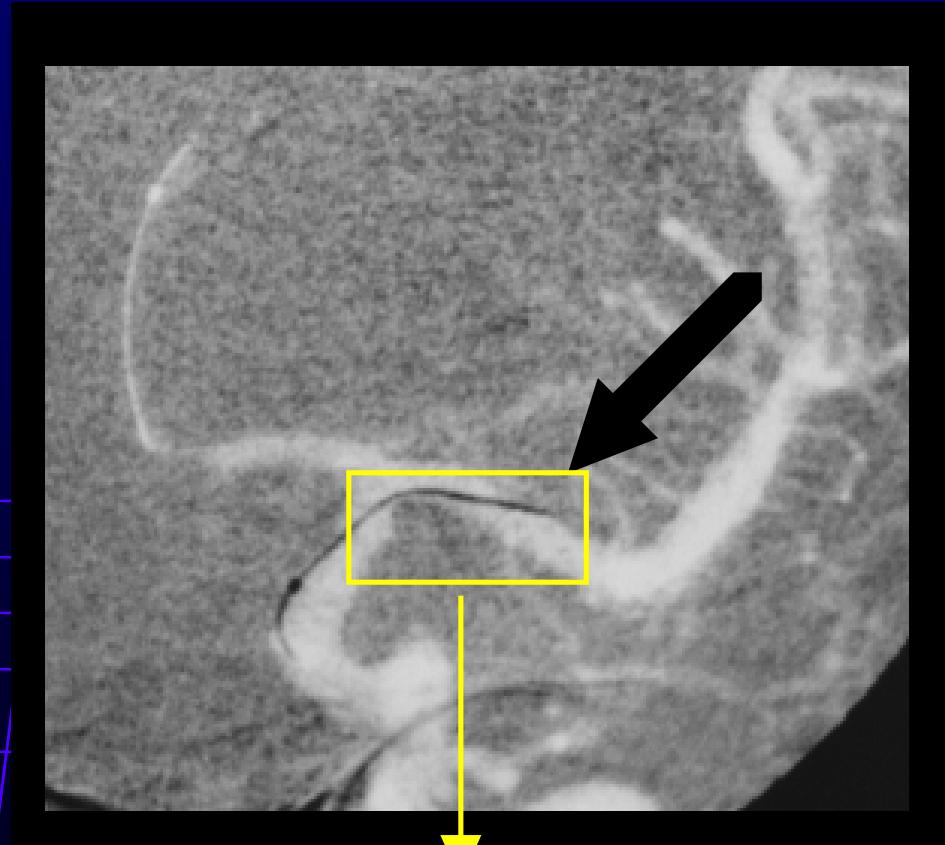


TDC Valiation - II

- TCD Mapping



FloWire



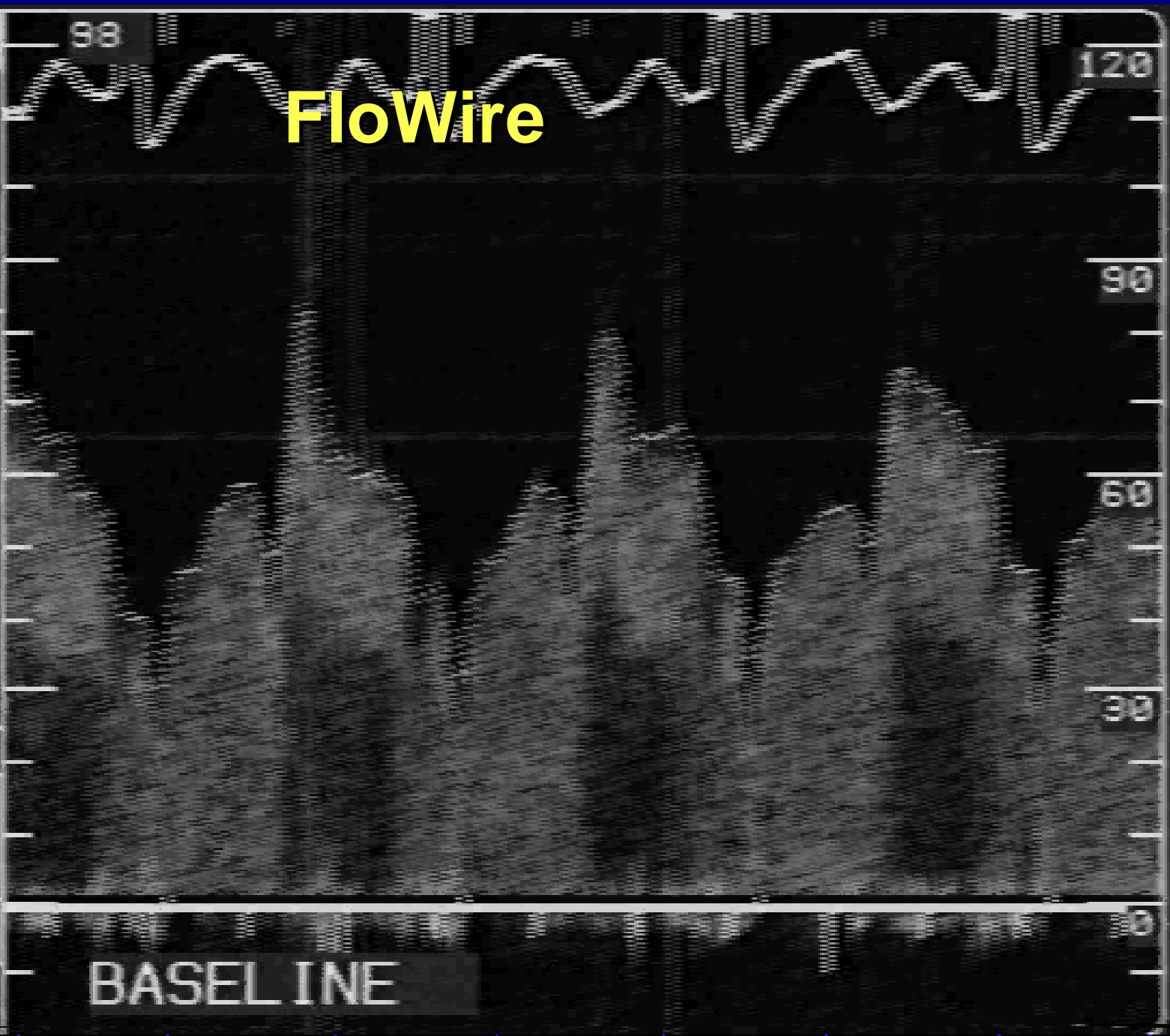
CARDIOMETRICS

11765

15:35:00
14 DEC 98 ↑F

APV:56
MPV:80
DSVR:1.2
DPVi:21

CFR APVs
BAPV:32
PAPV:
RATIO:
THR:30 P#:17

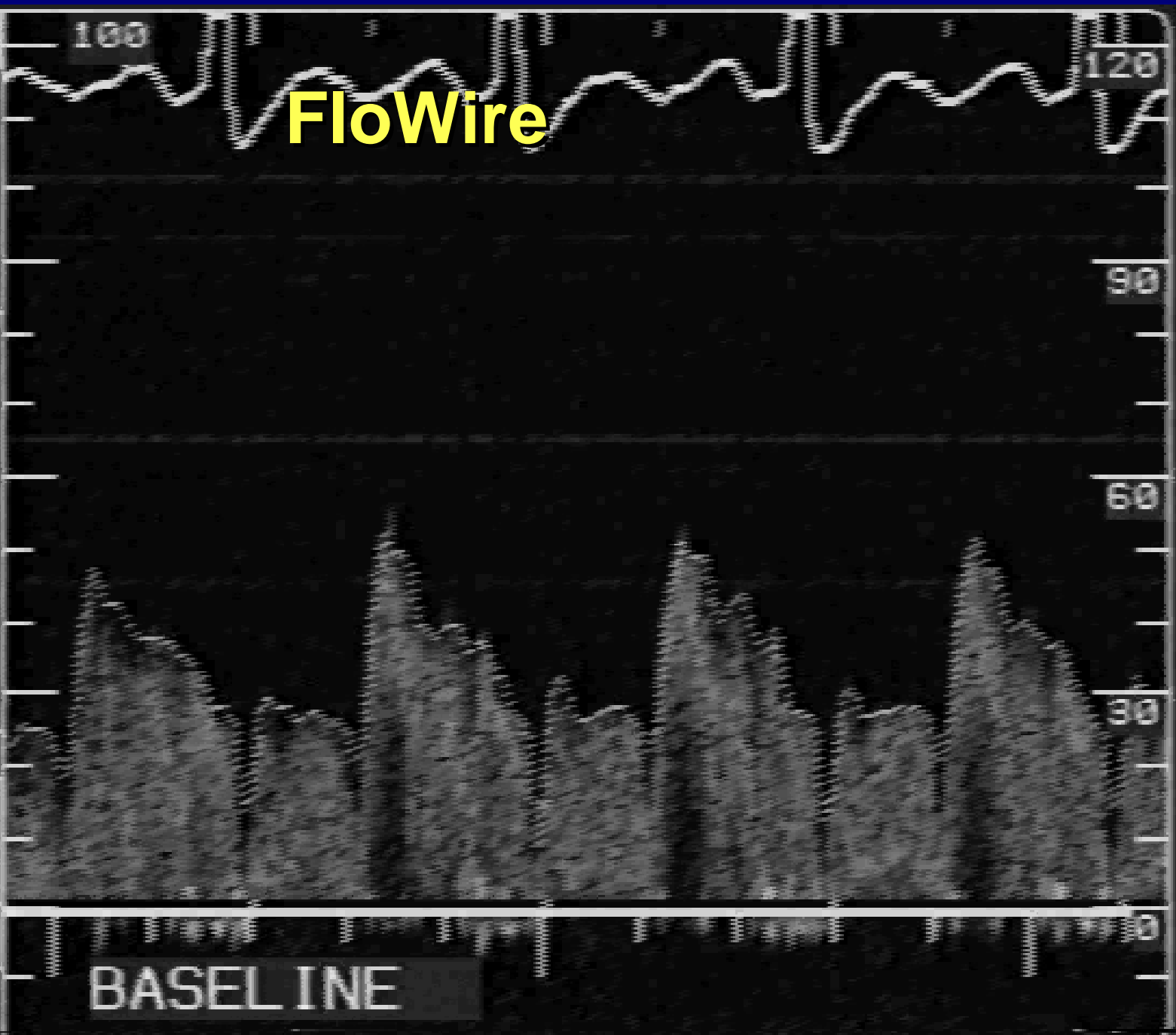


CARDIOMETRICS

11765
15:34:06
14 DEC 98 ↑F

APV:32
MPV:51
DSVR:1.4
DPVi:13

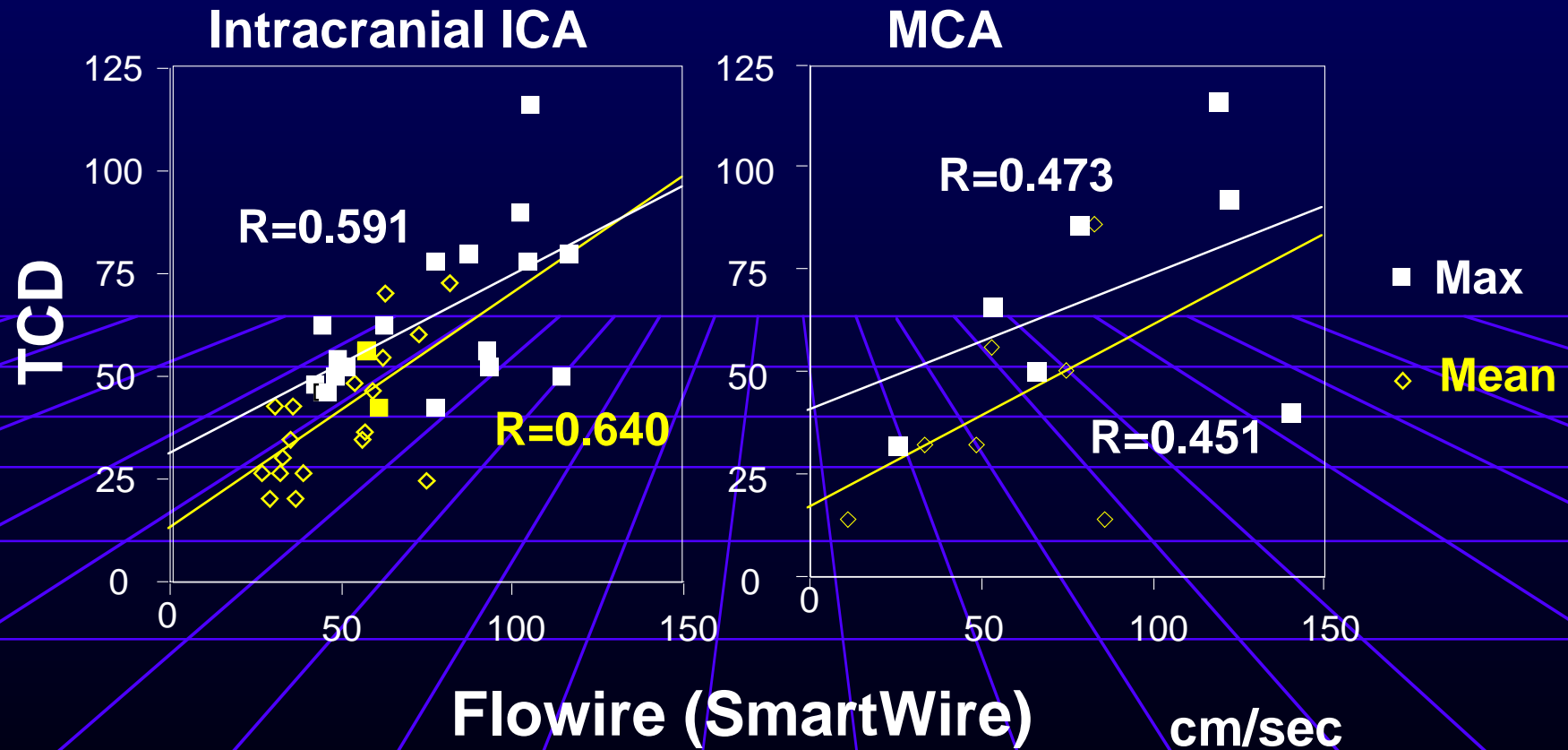
CFR APV_s
BAPV:32
PAPV:
RATIO:
THR:30 P#:17



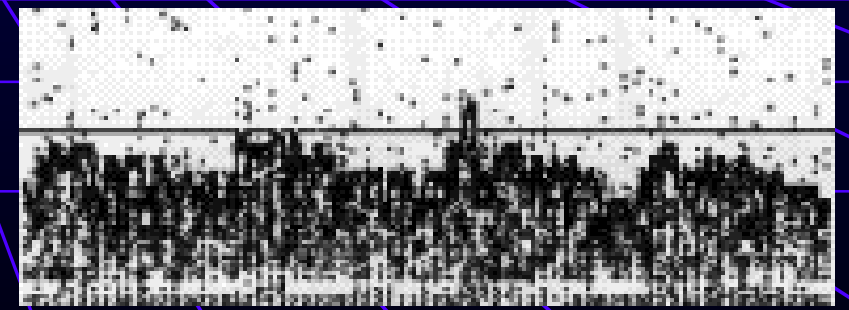
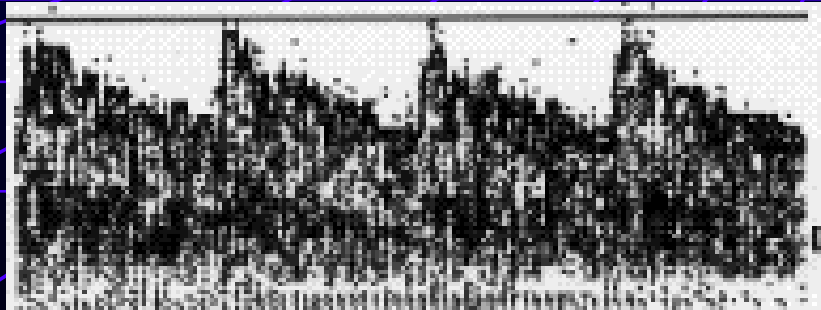
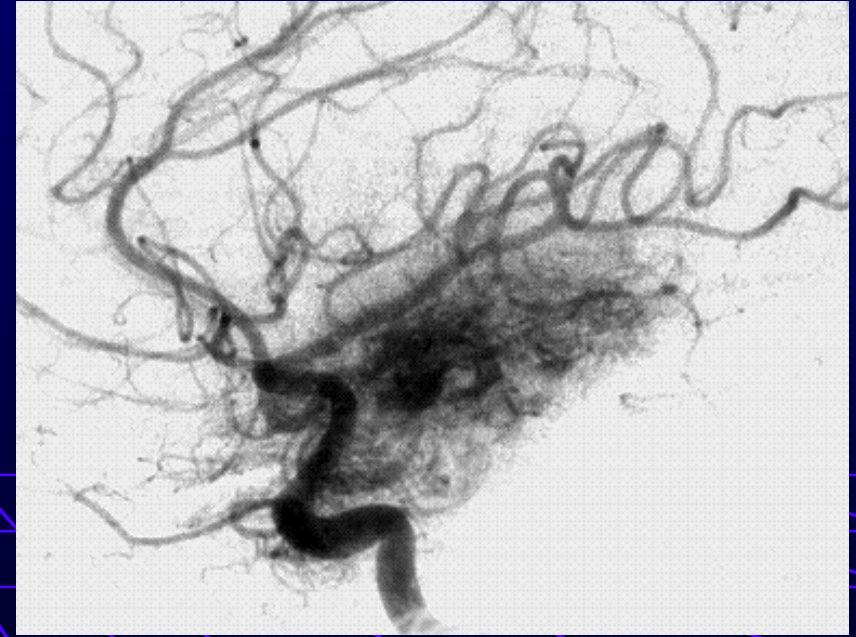
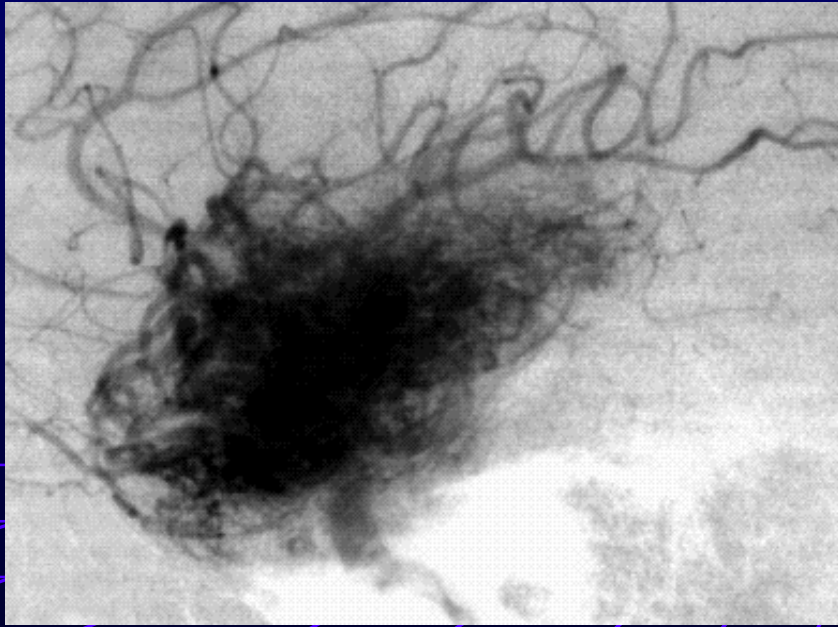
FloWire

BASELINE

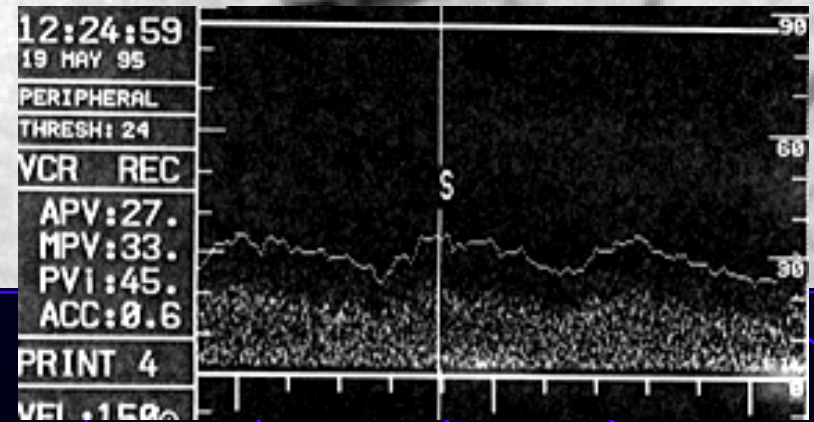
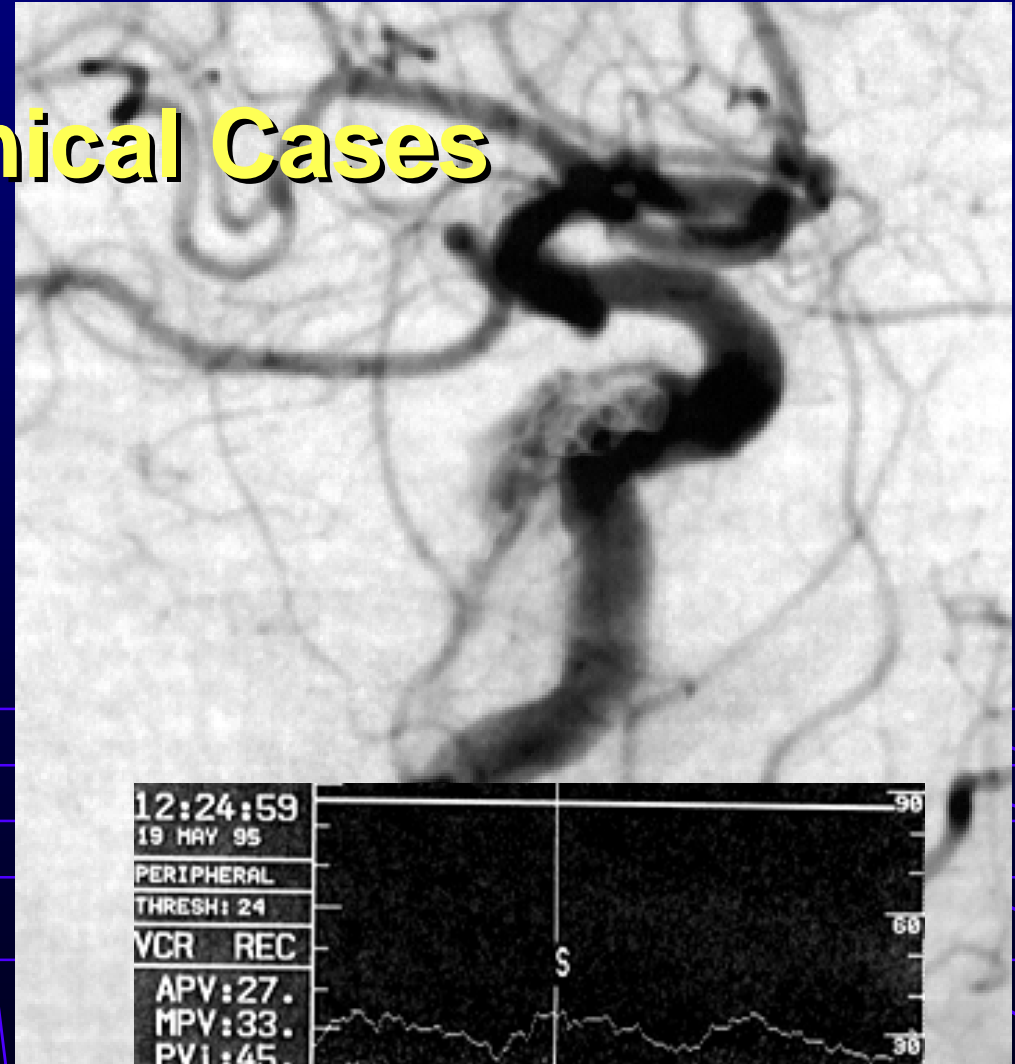
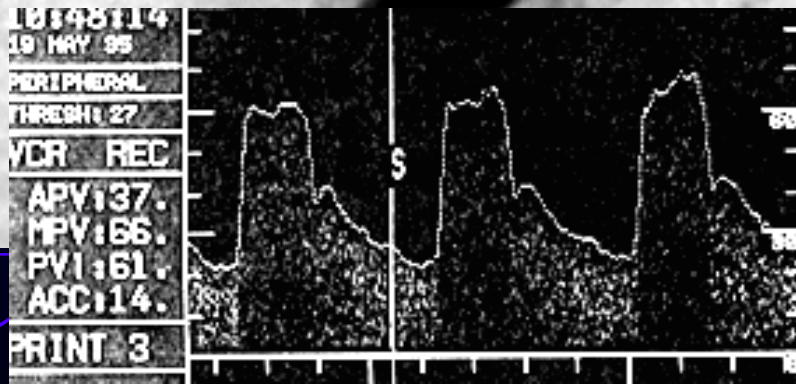
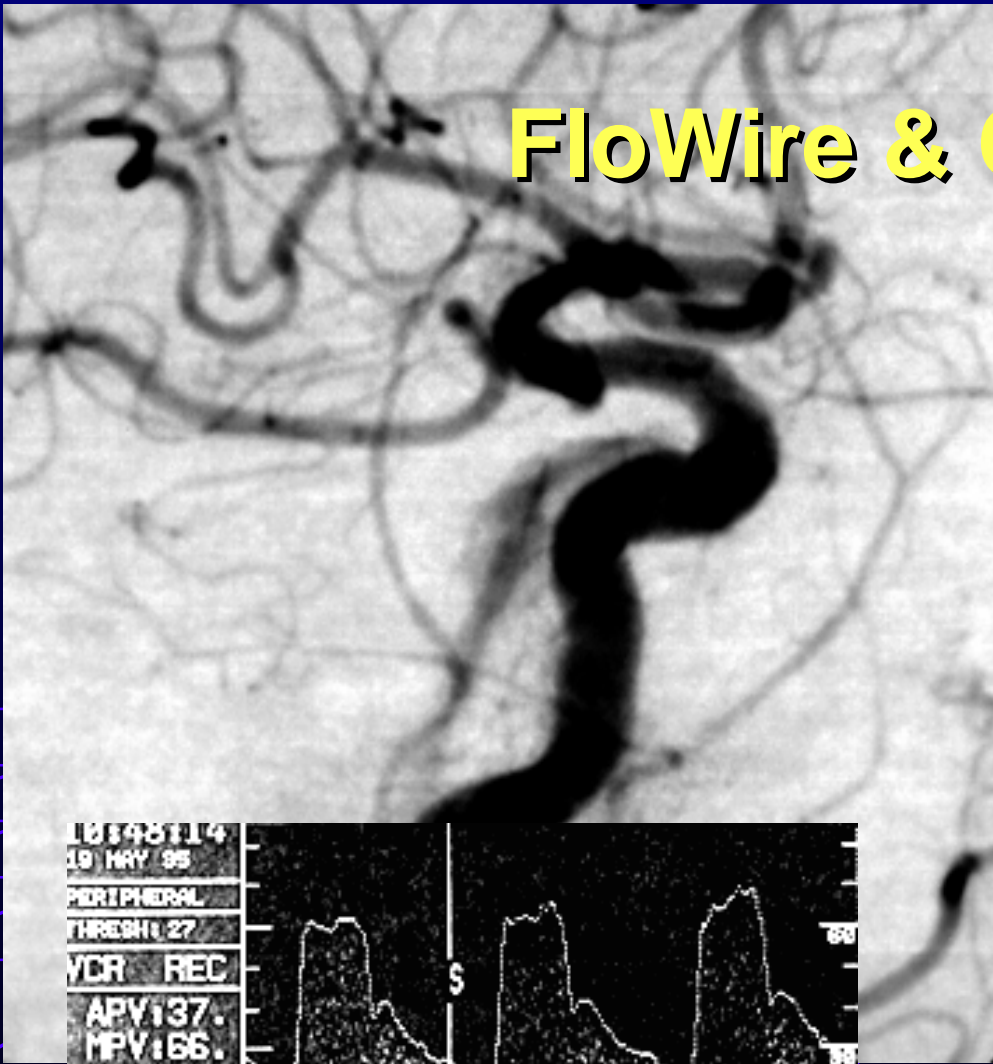
FloWire & TCD



FloWire & Clinical Cases

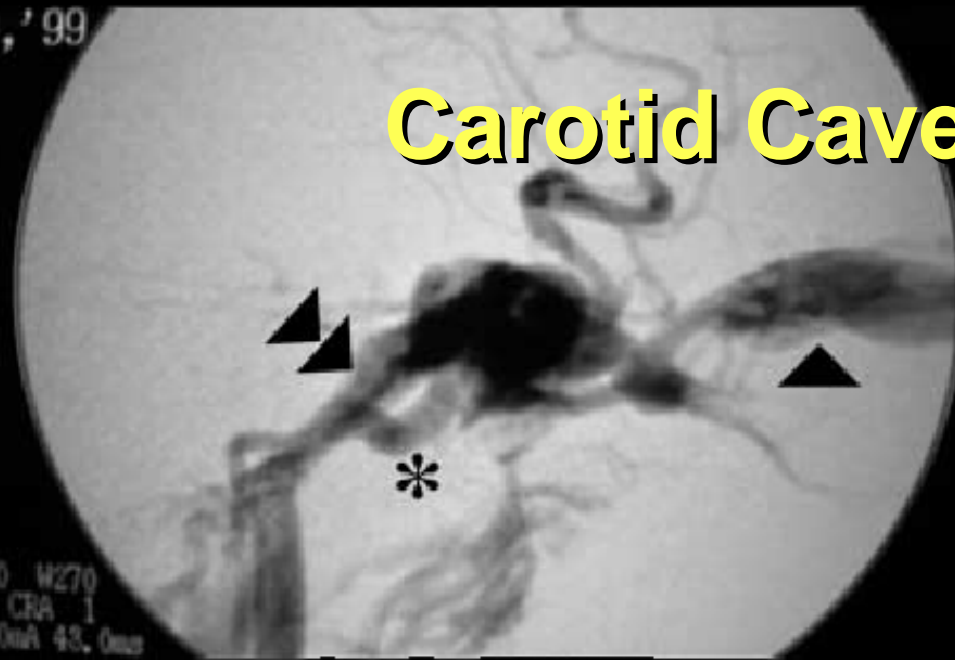


FloWire & Clinical Cases

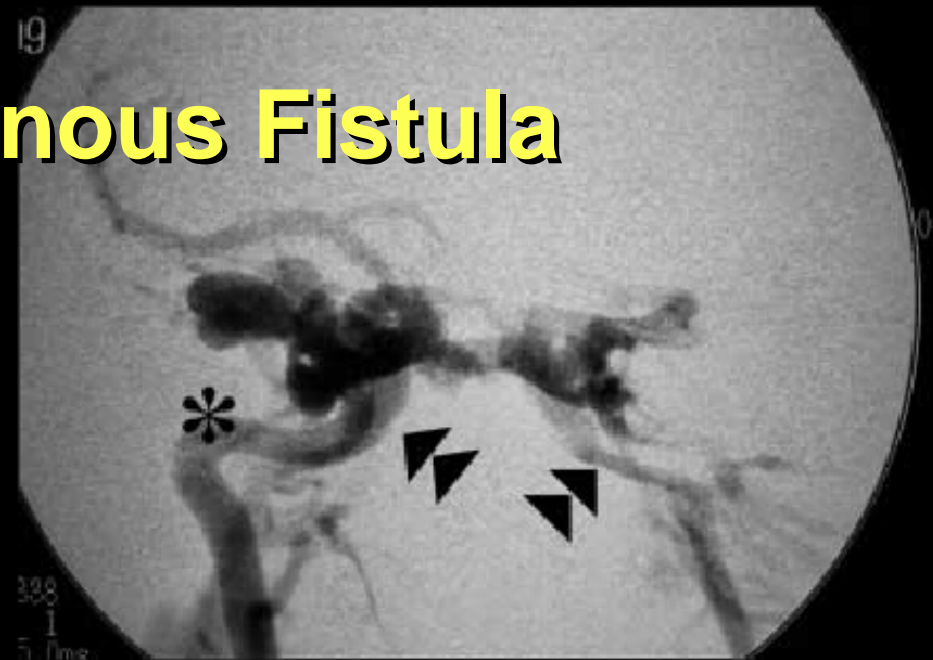


Carotid Cavernous Fistula

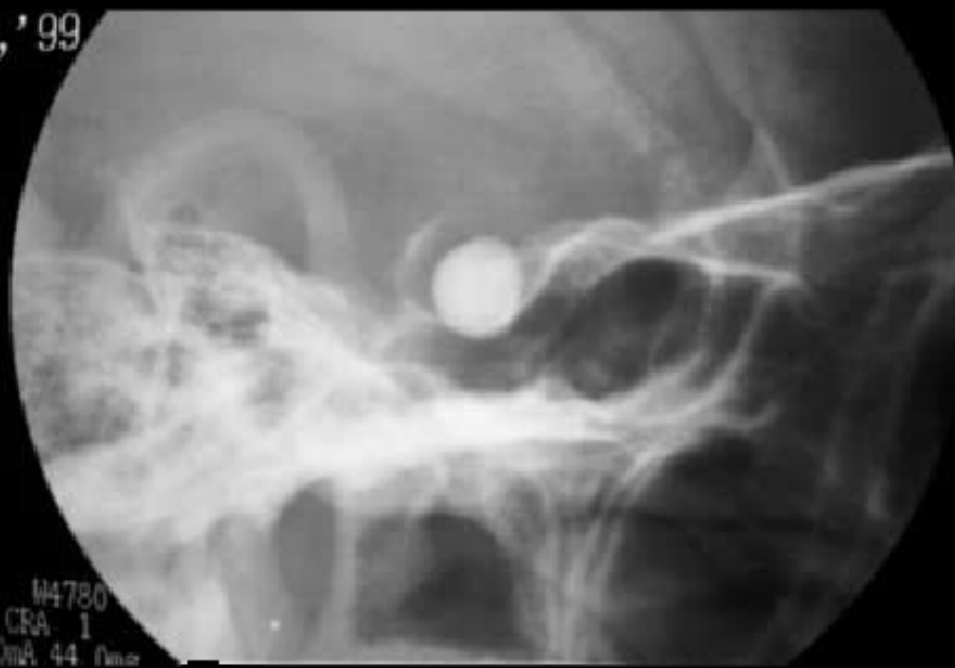9,'99



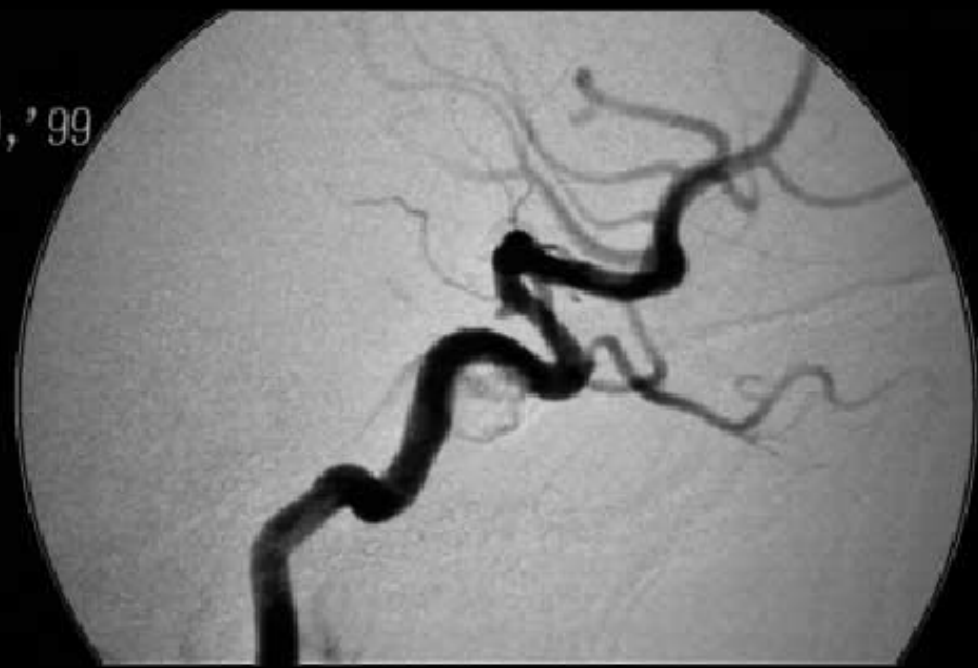19



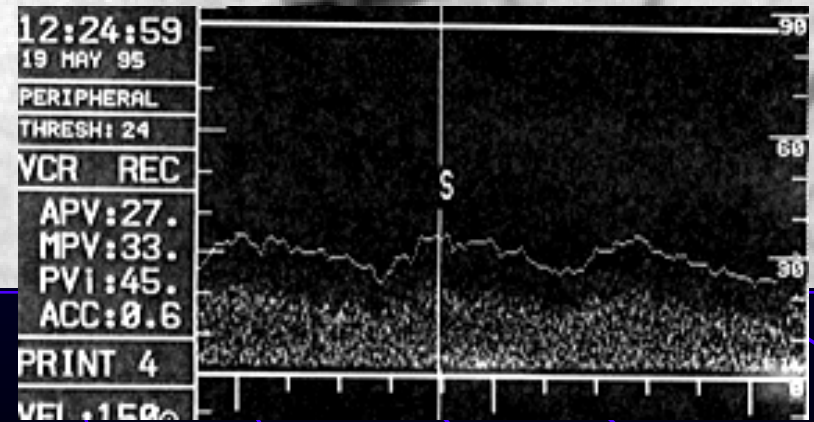
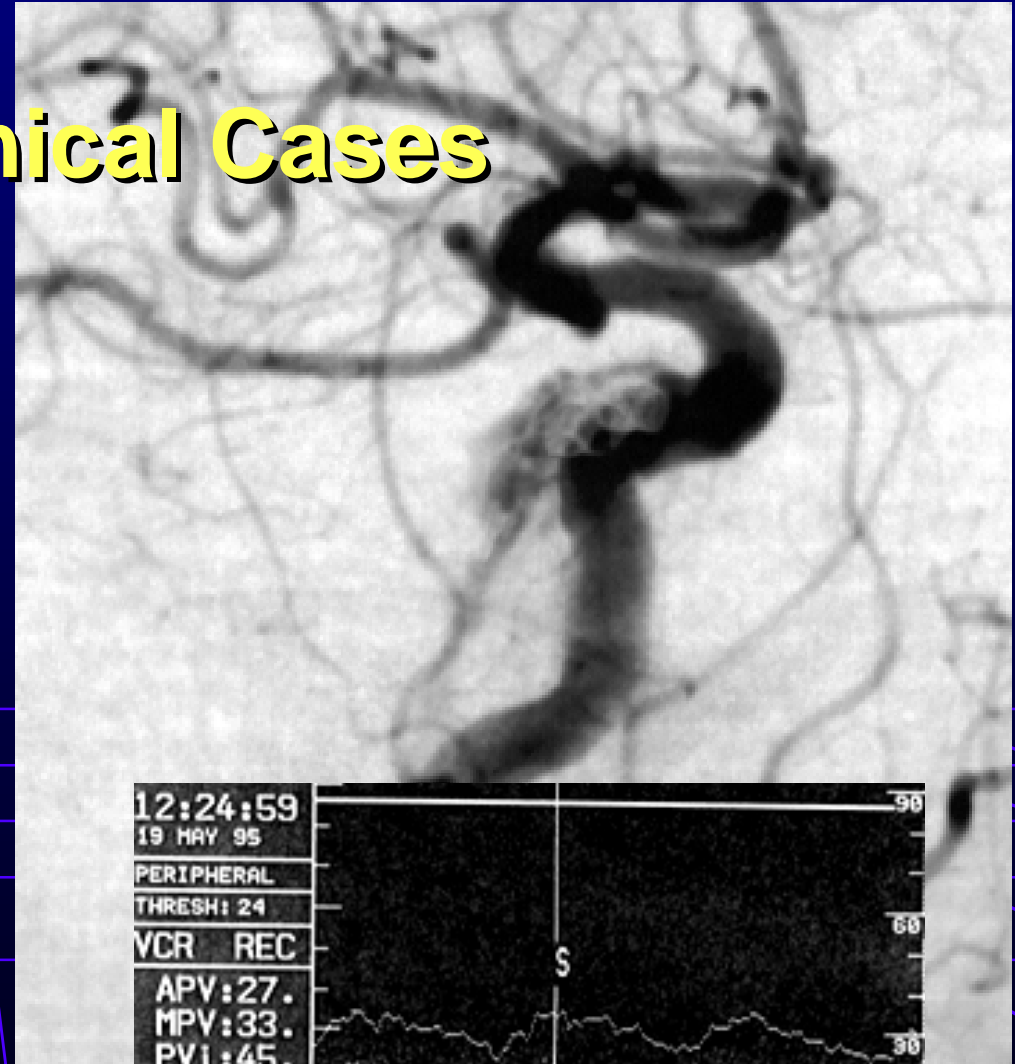
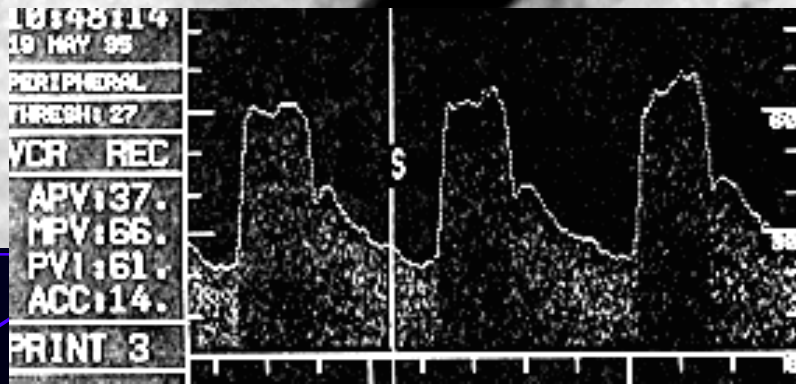
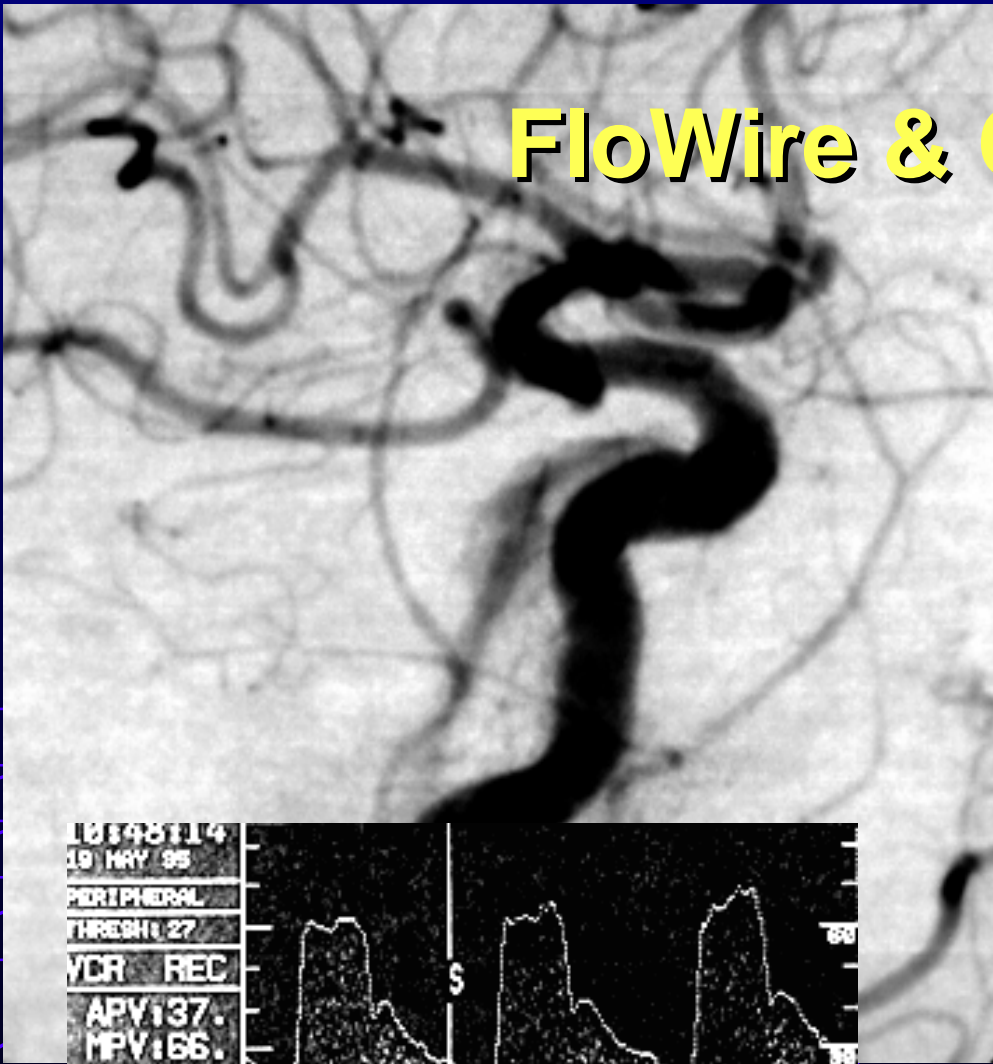
3,'99




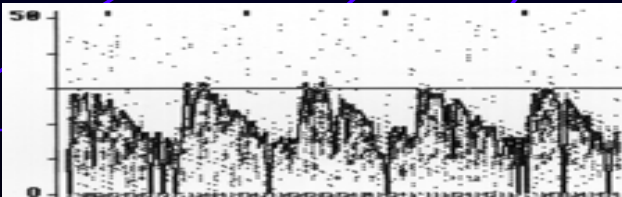
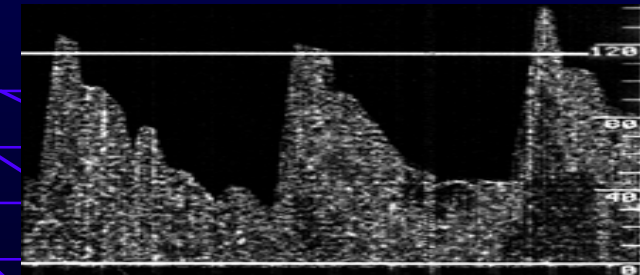

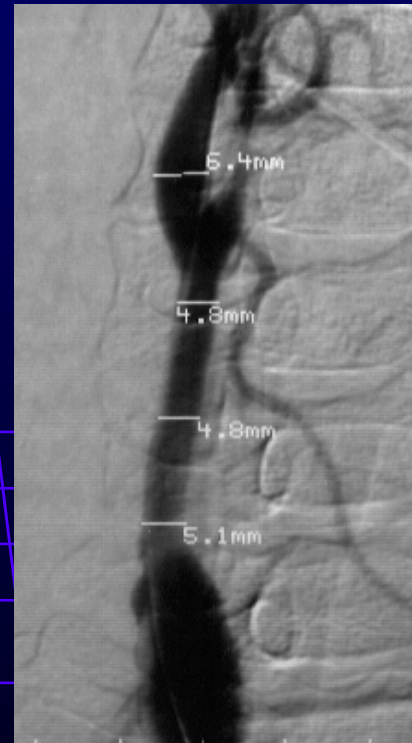
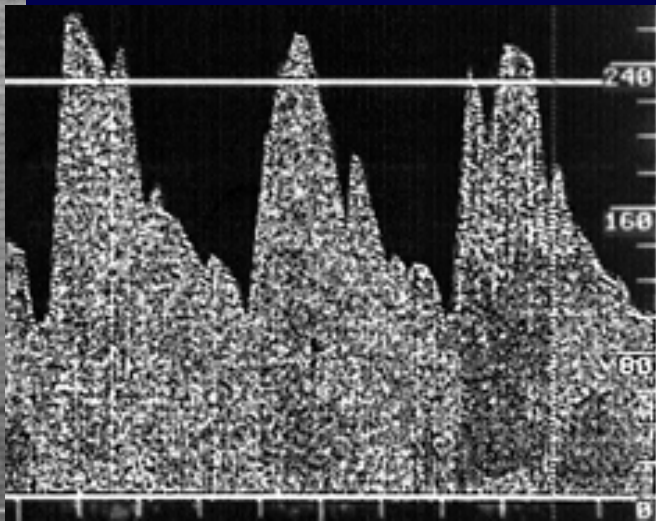

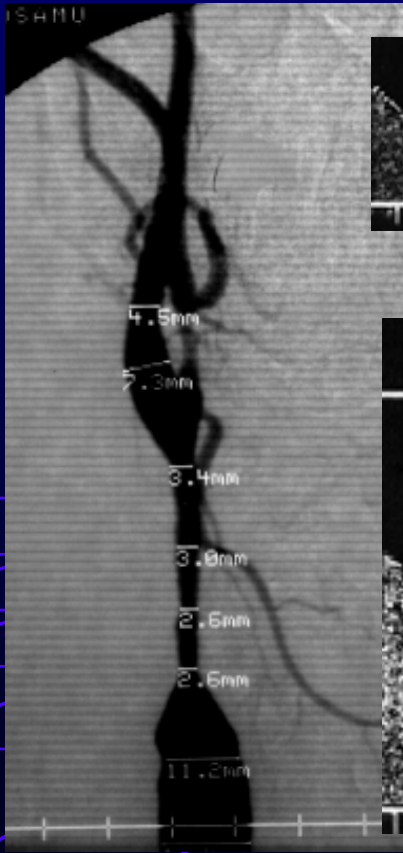
1,'99



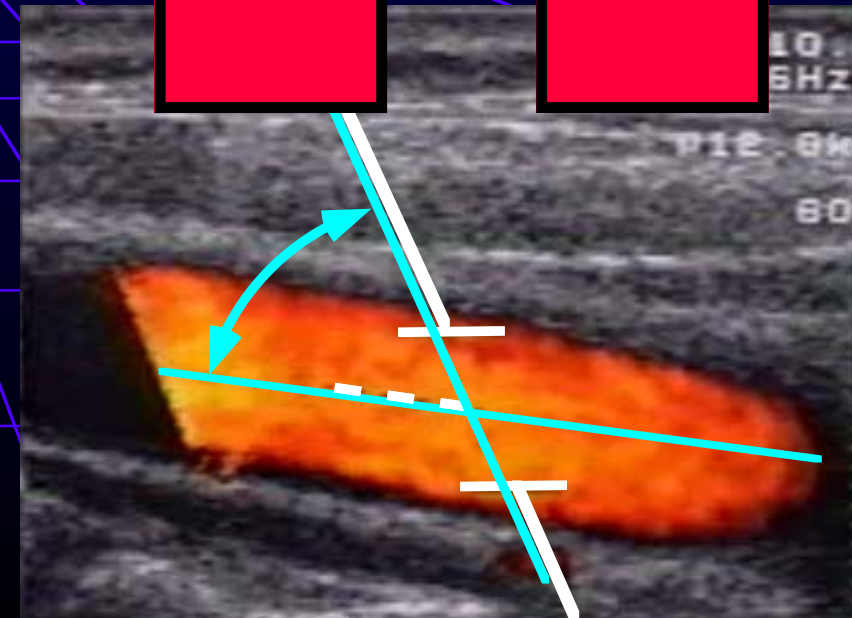
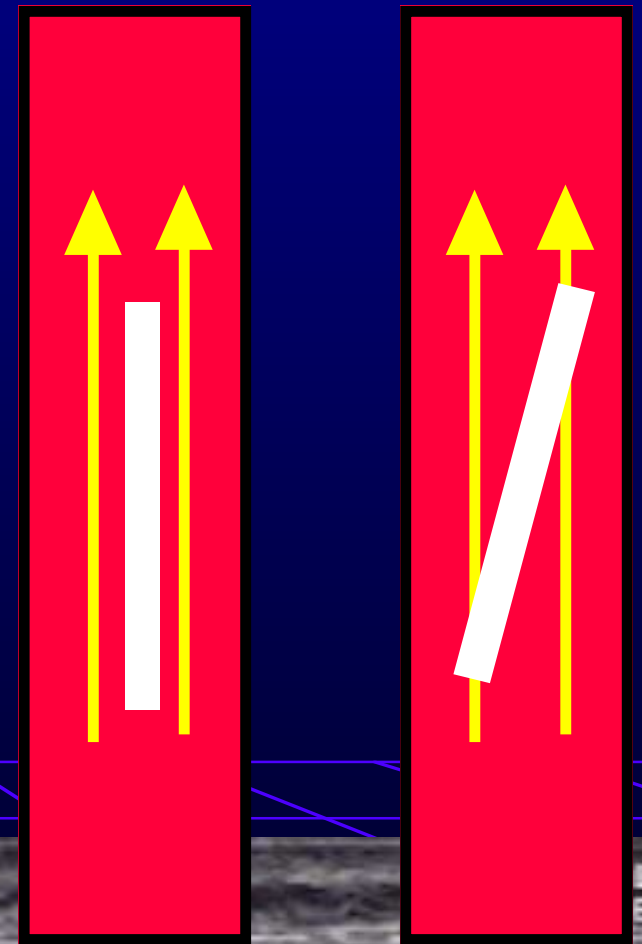

FloWire & Clinical Cases



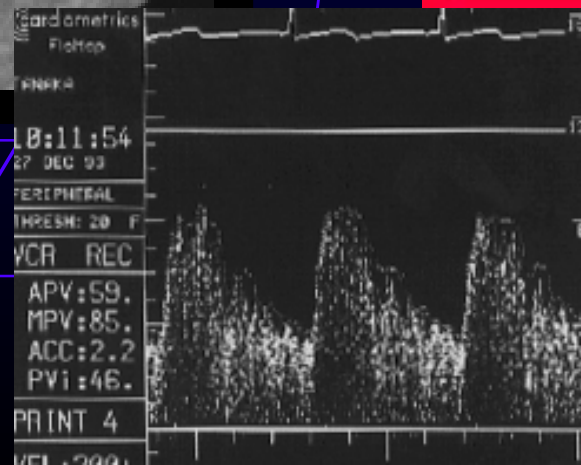
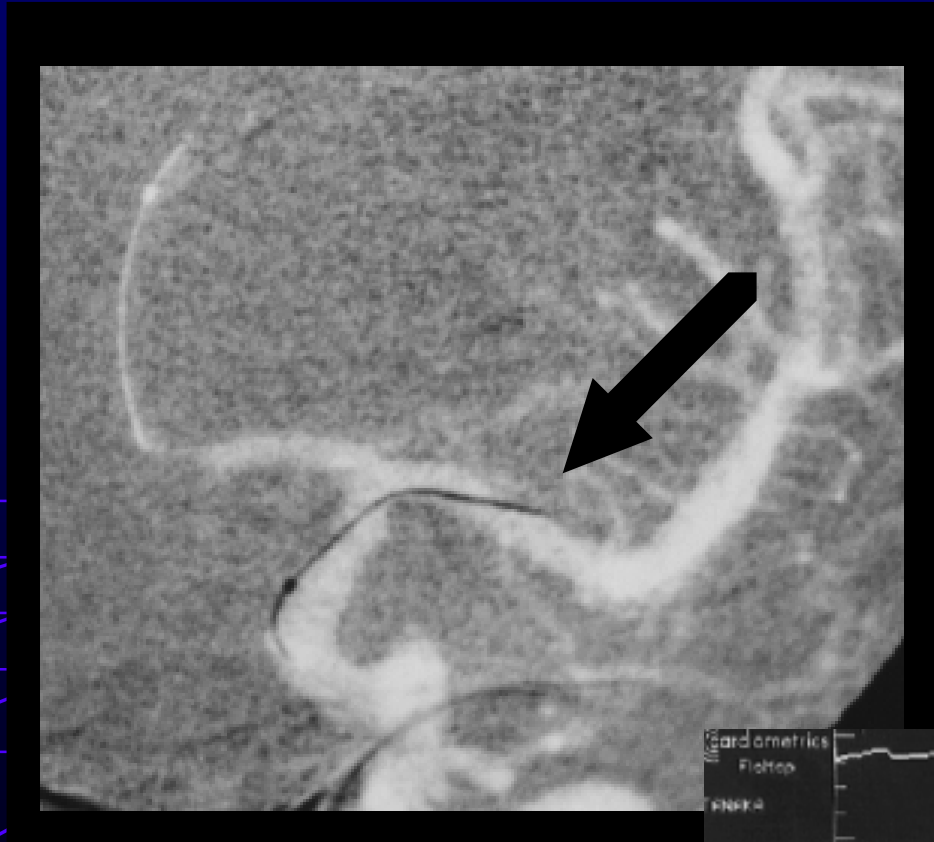
FloWire & Clinical Cases



Positioning?



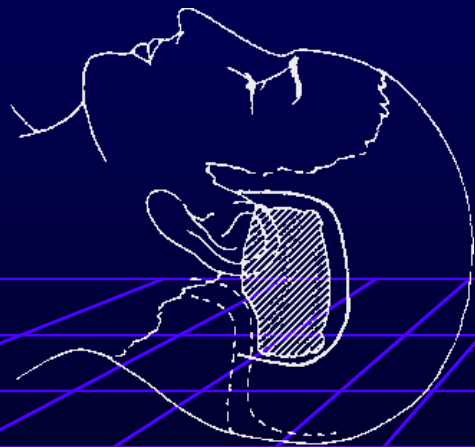
Positioning?



Positioning System (Image Guided Surgery)



"Webster" Positioning System



Magnetic Source
for Positioning



Conclusion

- Medical field, especially vascular surgery, demands CFD information.
- On the other hand, medical imaging modalities can offer 3D structure of vessels. At the same time, some information about boundary condition, medical modalities can offer, too.
- As the boundary condition, flow pattern assessment by magnetic resonance and Doppler sonography is presented.
- Doppler Sonography Needs to Work with Positioning System.