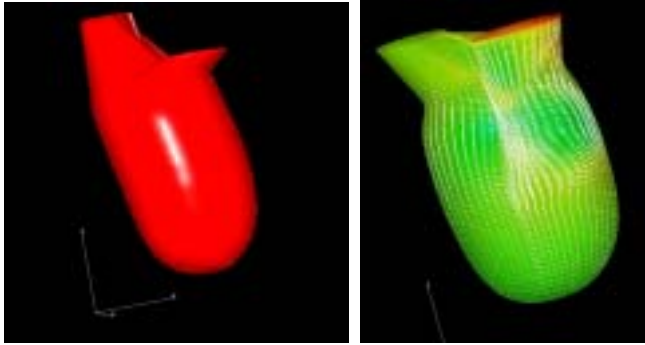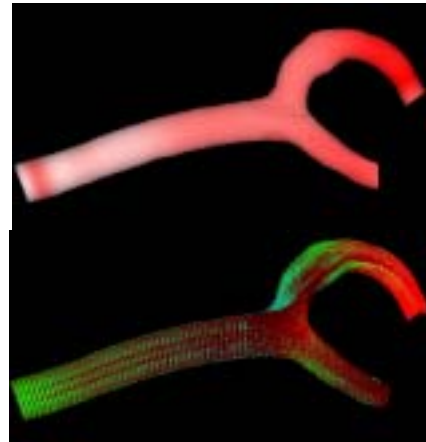
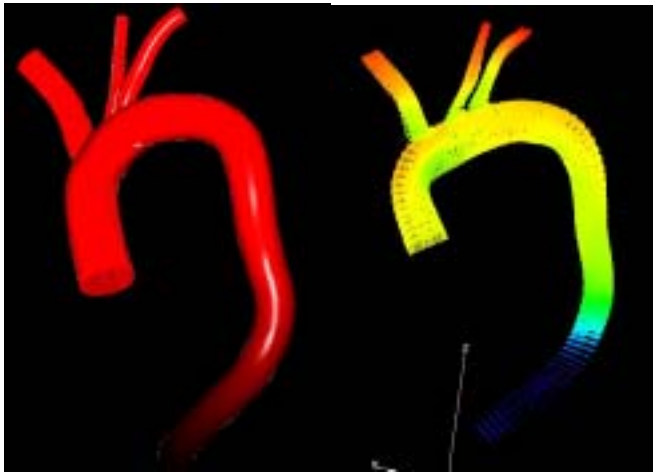



An US image-based LV model and a twin-vortex flow in early diastole




An after-operation, predicted carotid artery model and flow pattern in mid systole



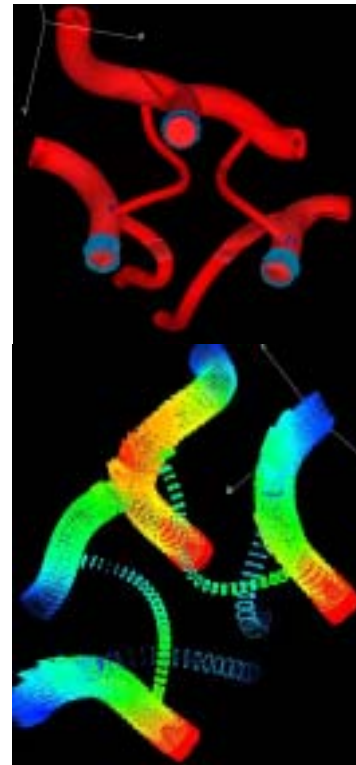
A CT-image-based aorta model and flow pattern in mid systole



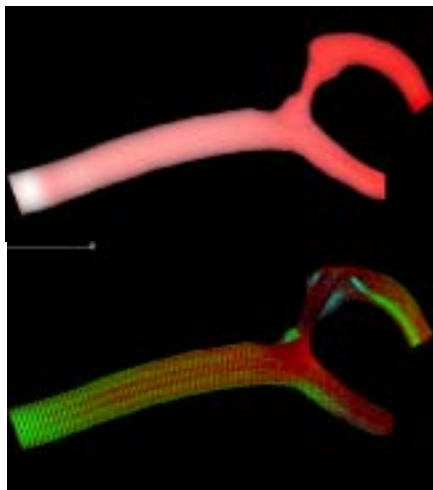
A CT-image-based renal artery model and flow pattern in mid systole



An EC model at aortic arch top and shear stress dist. In mid systole



A CT-image-based willis ring model and flow pattern in mid systole



A X-ray-image-based, stenosed carotid artery model and flow pattern in mid systole